



CASE 01

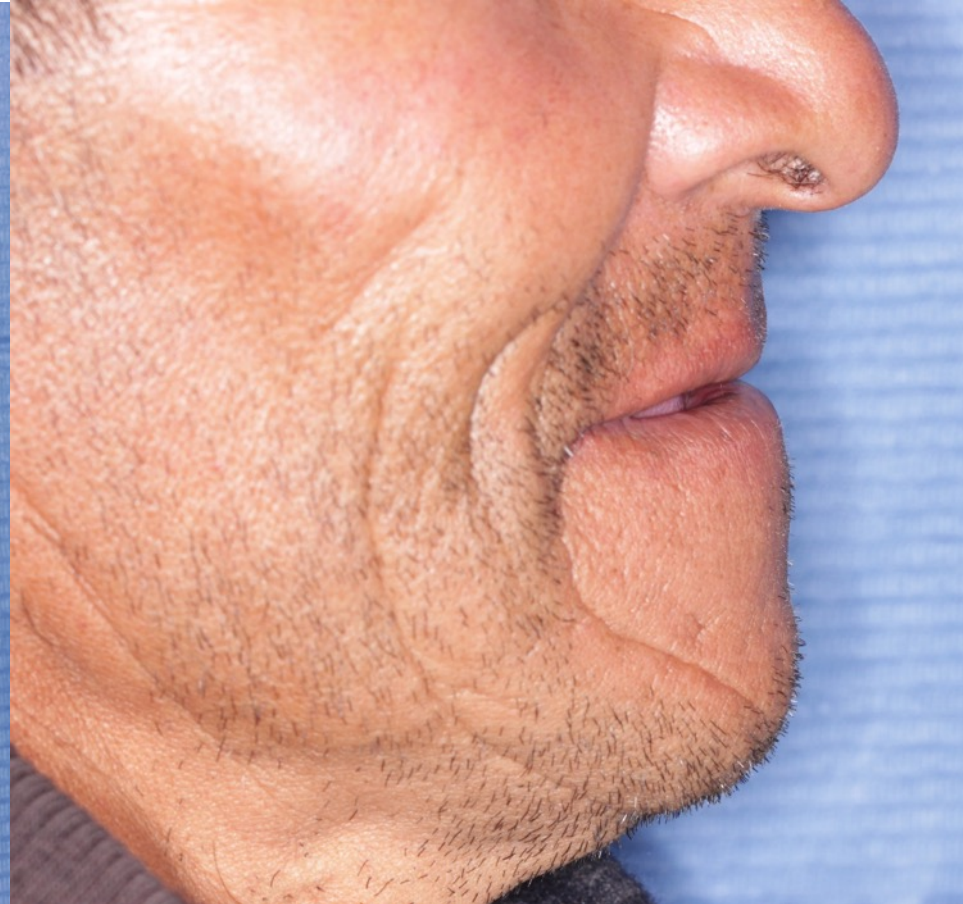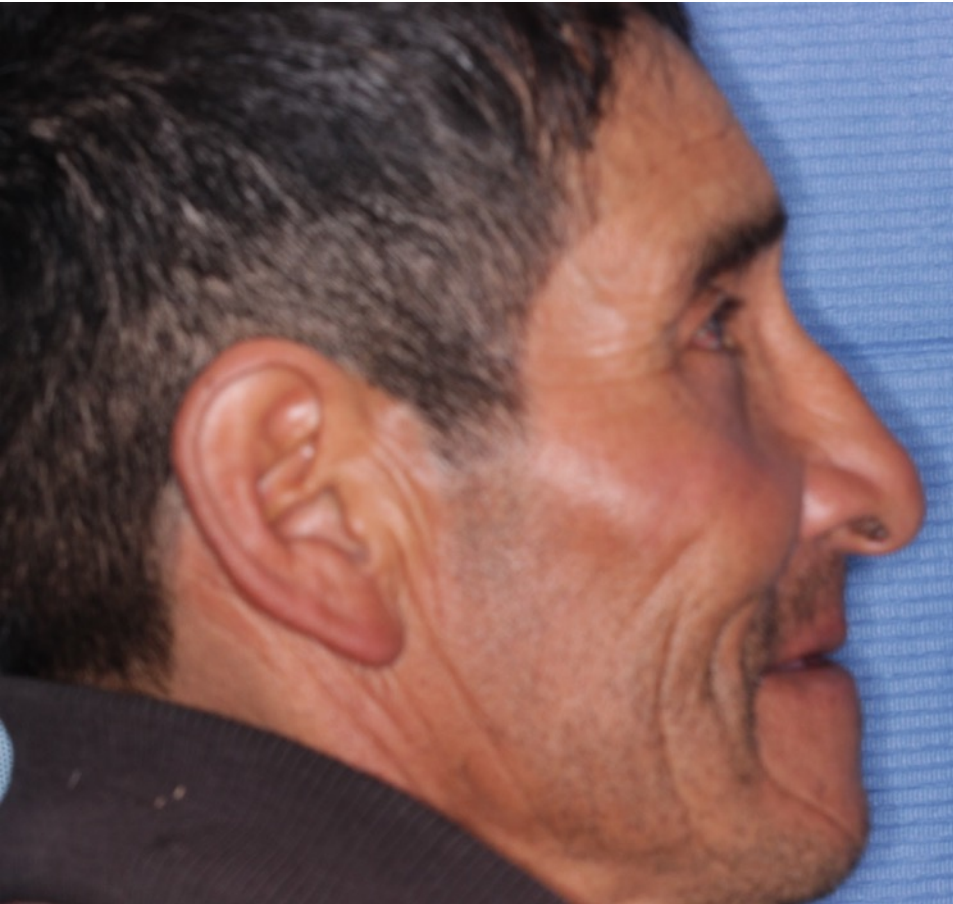GENERAL INFORMATION:

- **Sex:** Masculine
- **Age:** 64
- **Address:** Pacchanta – Occongate, Cusco - Perú
- **Occupation:** Farmer

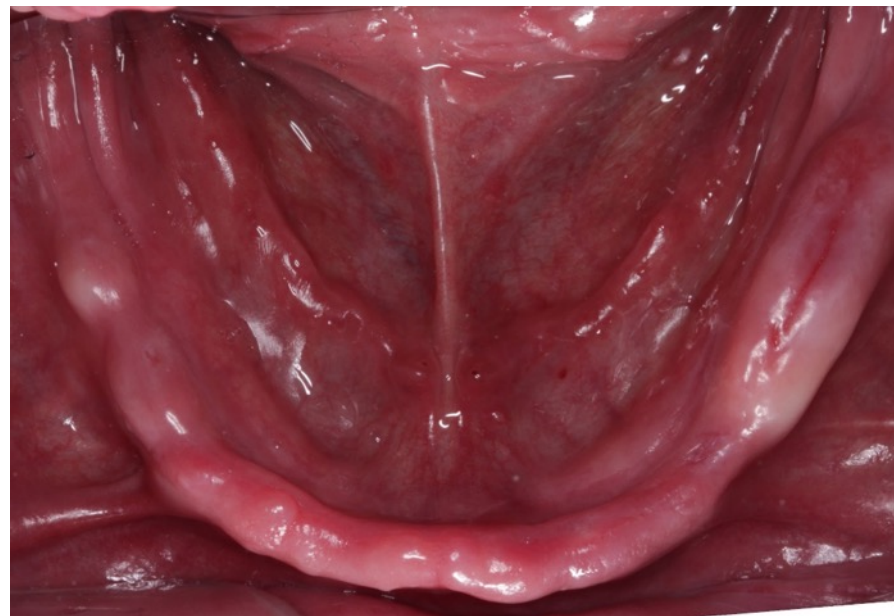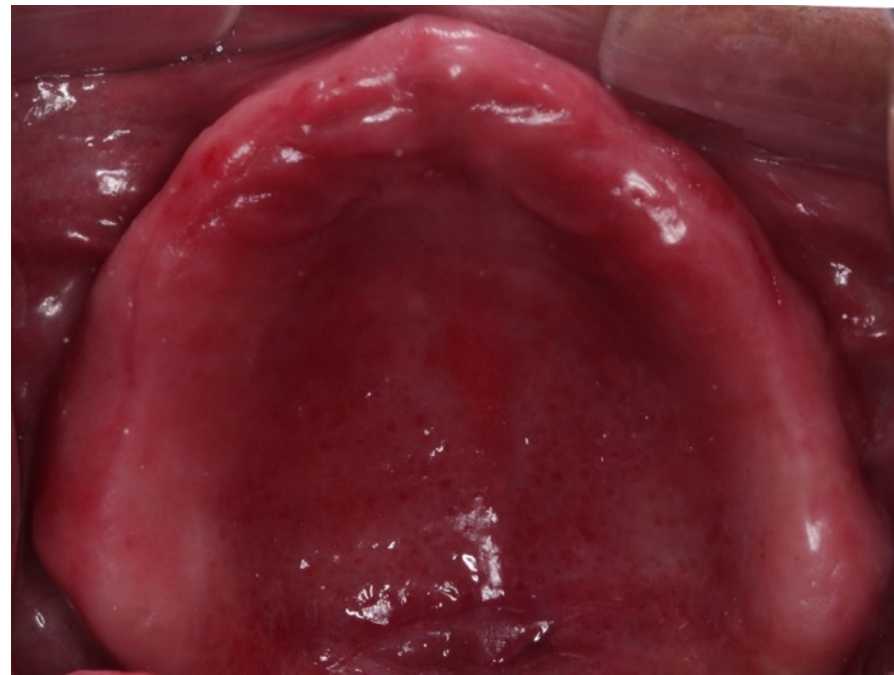
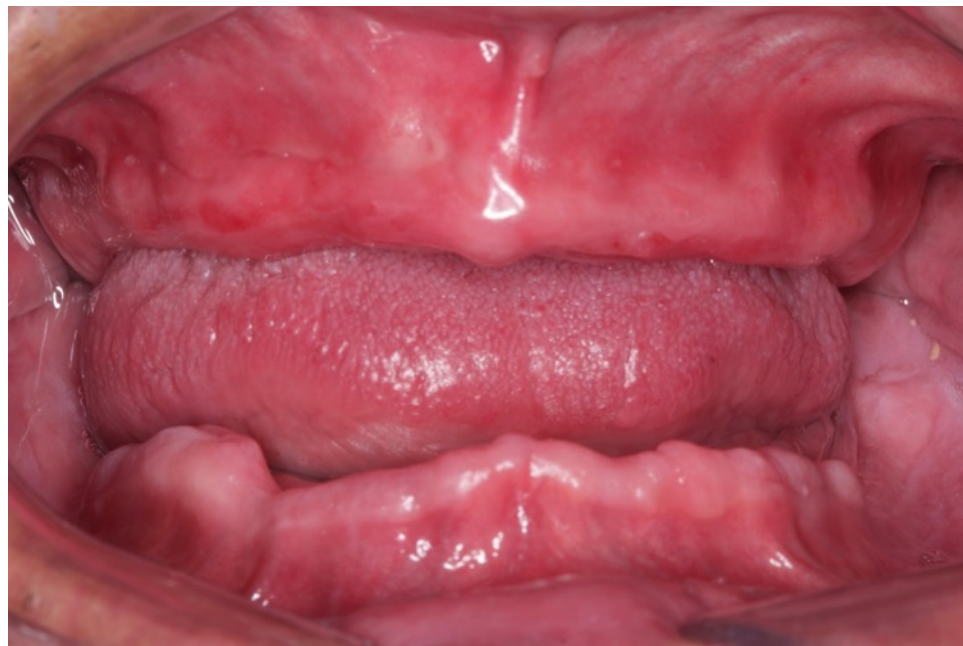EXTRA ORAL EXAM - FRONTAL



EXTRA ORAL EXAM - PROFILE



INTRAORAL EXAM



DIAGNOSIS

- Edéntulous Total Bimaxilar

TREATMENT PLAN

- Total Bimaxilar Prosthesis

PROGNOSIS

- Favorable

CLINICAL PROTOCOL

CLINICAL PROTOCOL

**1st
session**

- Clinical exam
- Primary impressions
- Customized trays

**2nd
session**

- Final impressions

**3rd
session**

- Intermaxillary registration
- Articulator
- Artificial teeth selection

CLINICAL PROTOCOL

4th
session

- Teeth try in

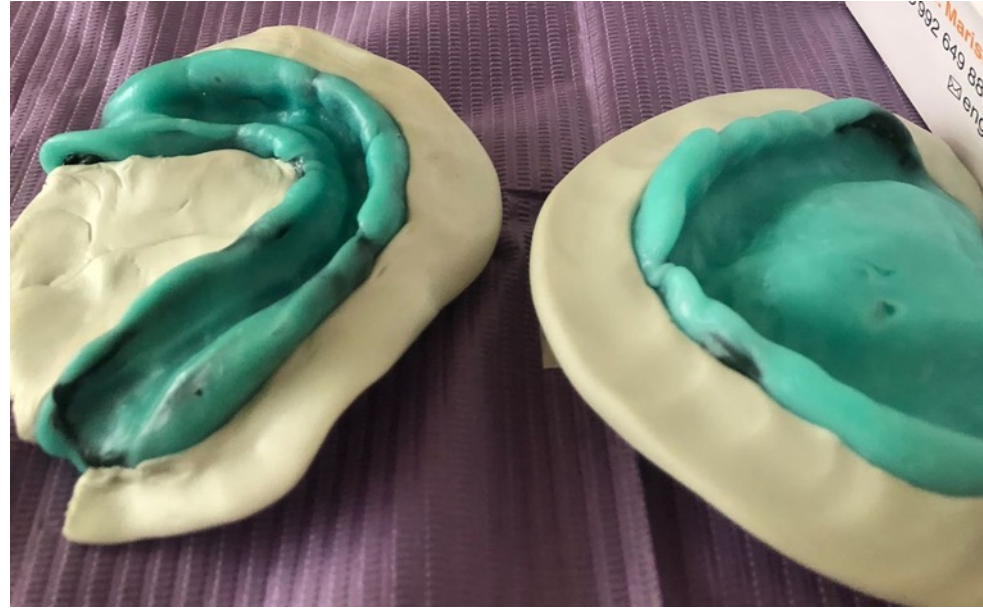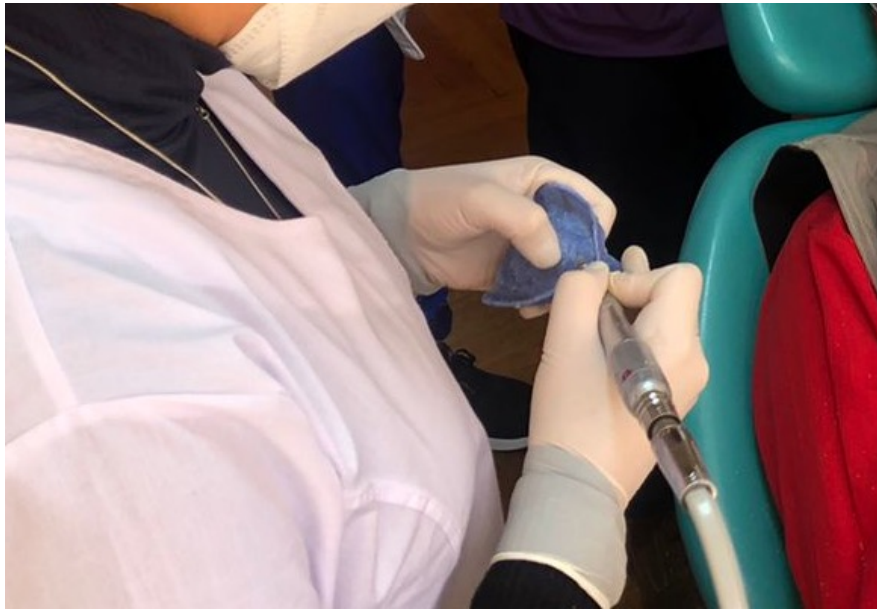5th
session

- Installation

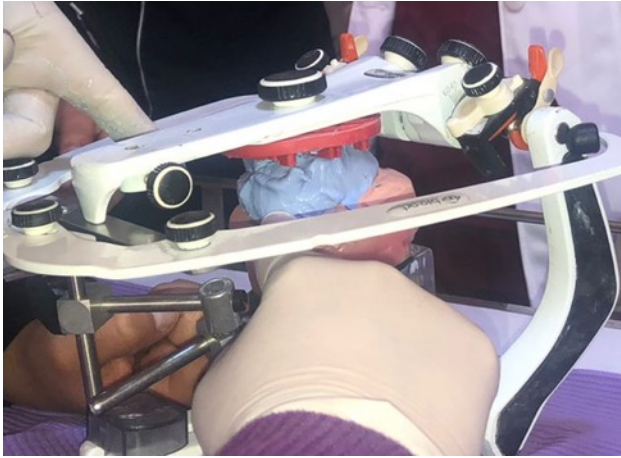
6th
session

- Follow up

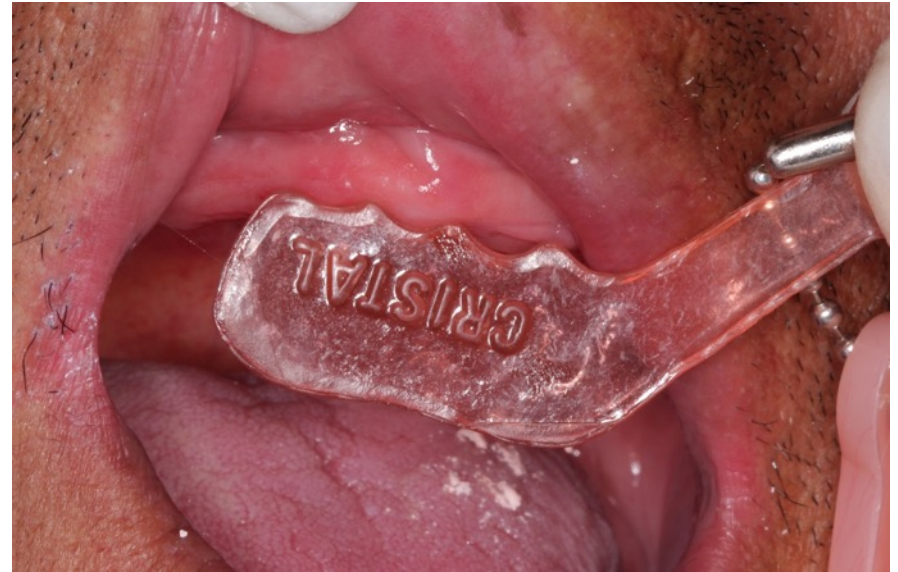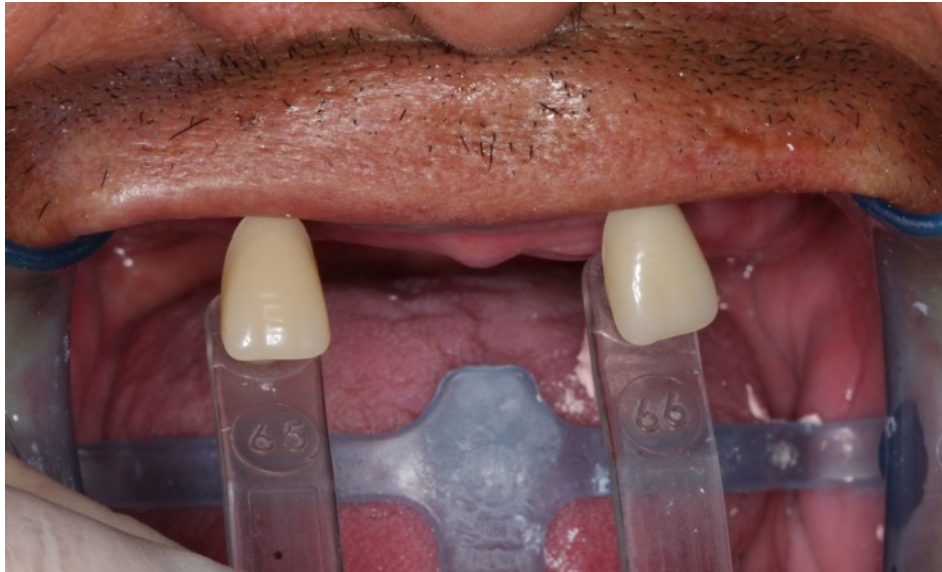➤ CUSTOMIZED TRAY AND DEFINITIVE IMPRESSION



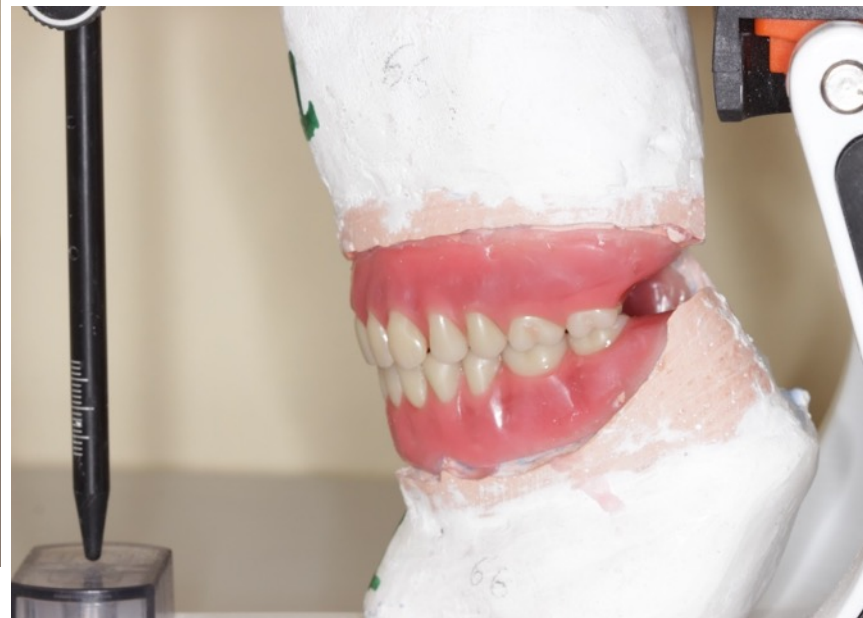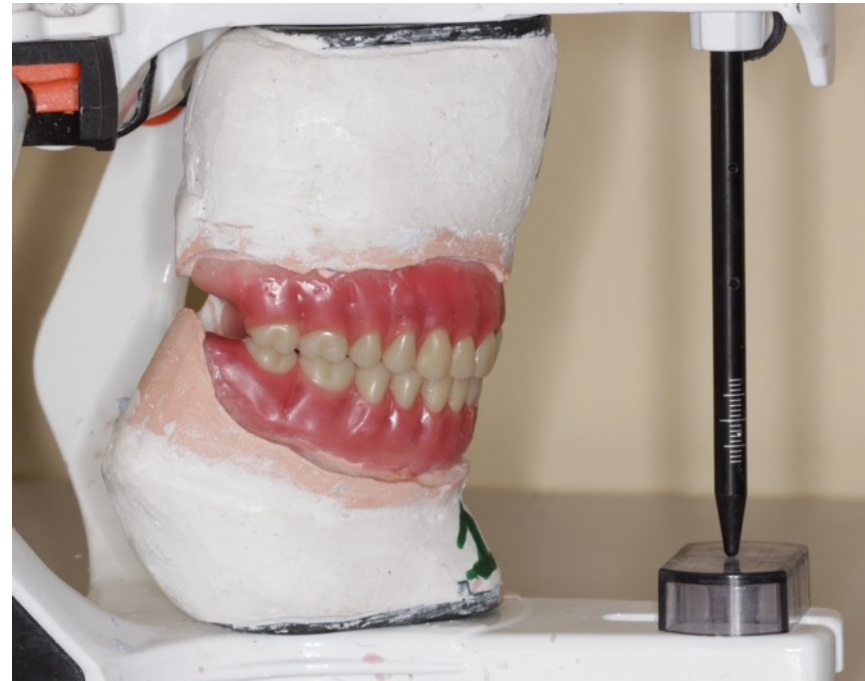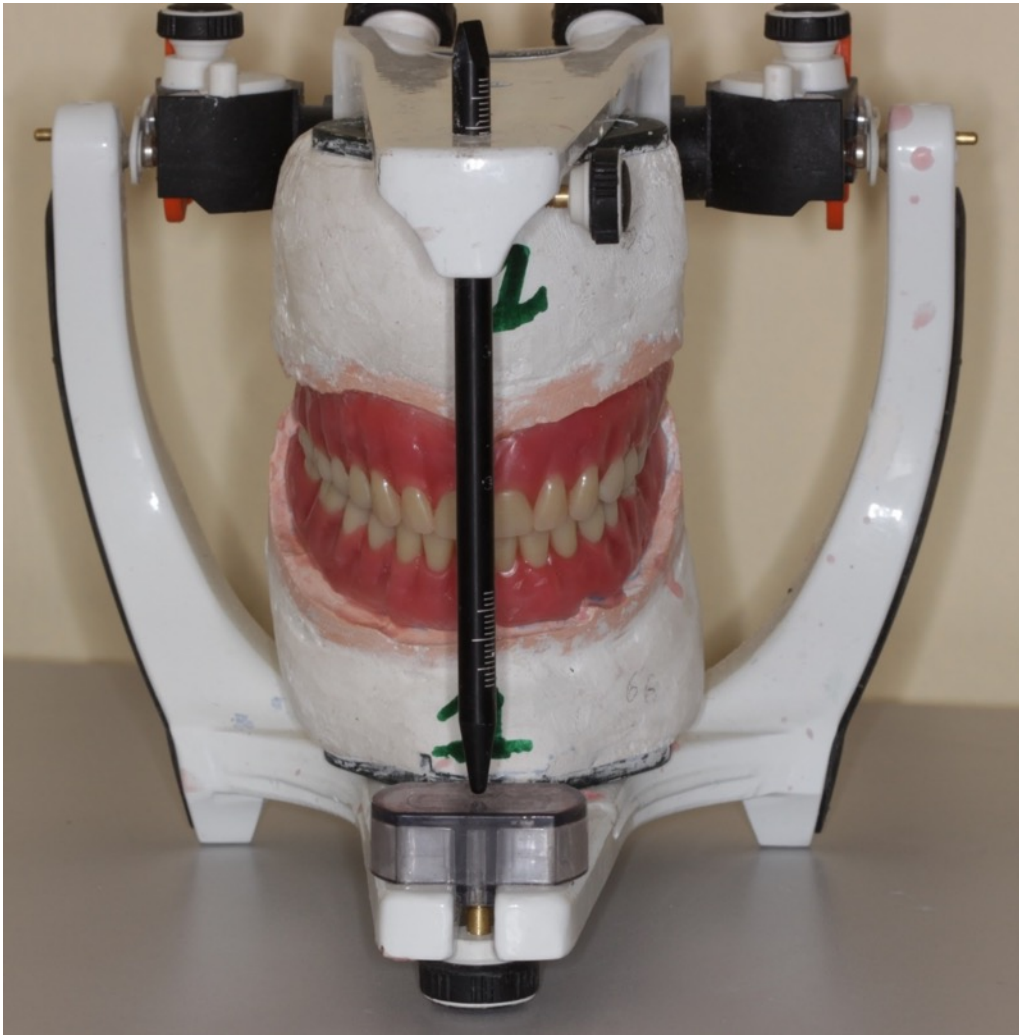➤ ARTICULATION



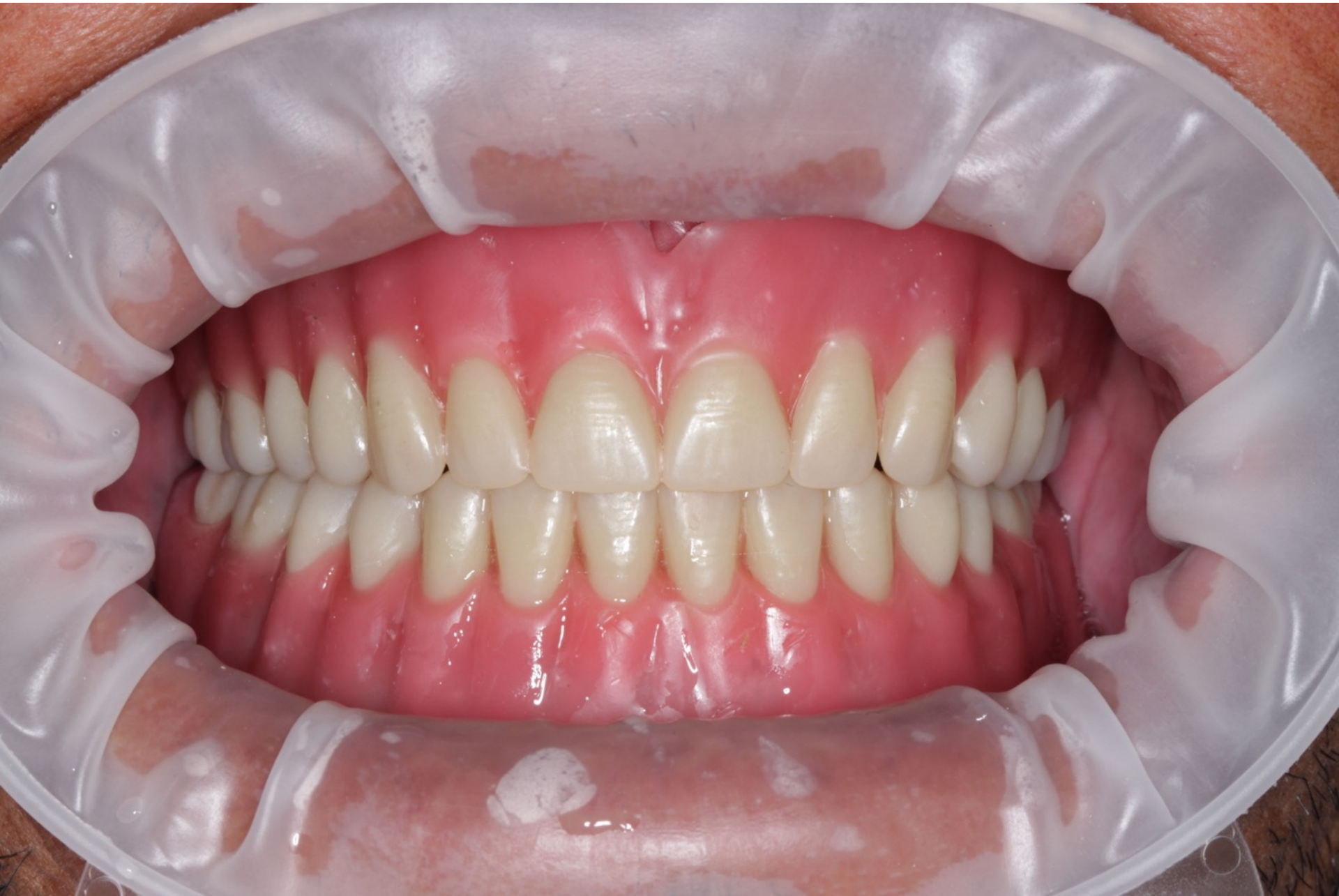➤ ARTIFICIAL TEETH SELECTION



➤ TEETH WAX UP



➤ TEETH TRY IN



➤ TEETH TRY IN



Regular position

Smiling

➤ TEETH TRY IN

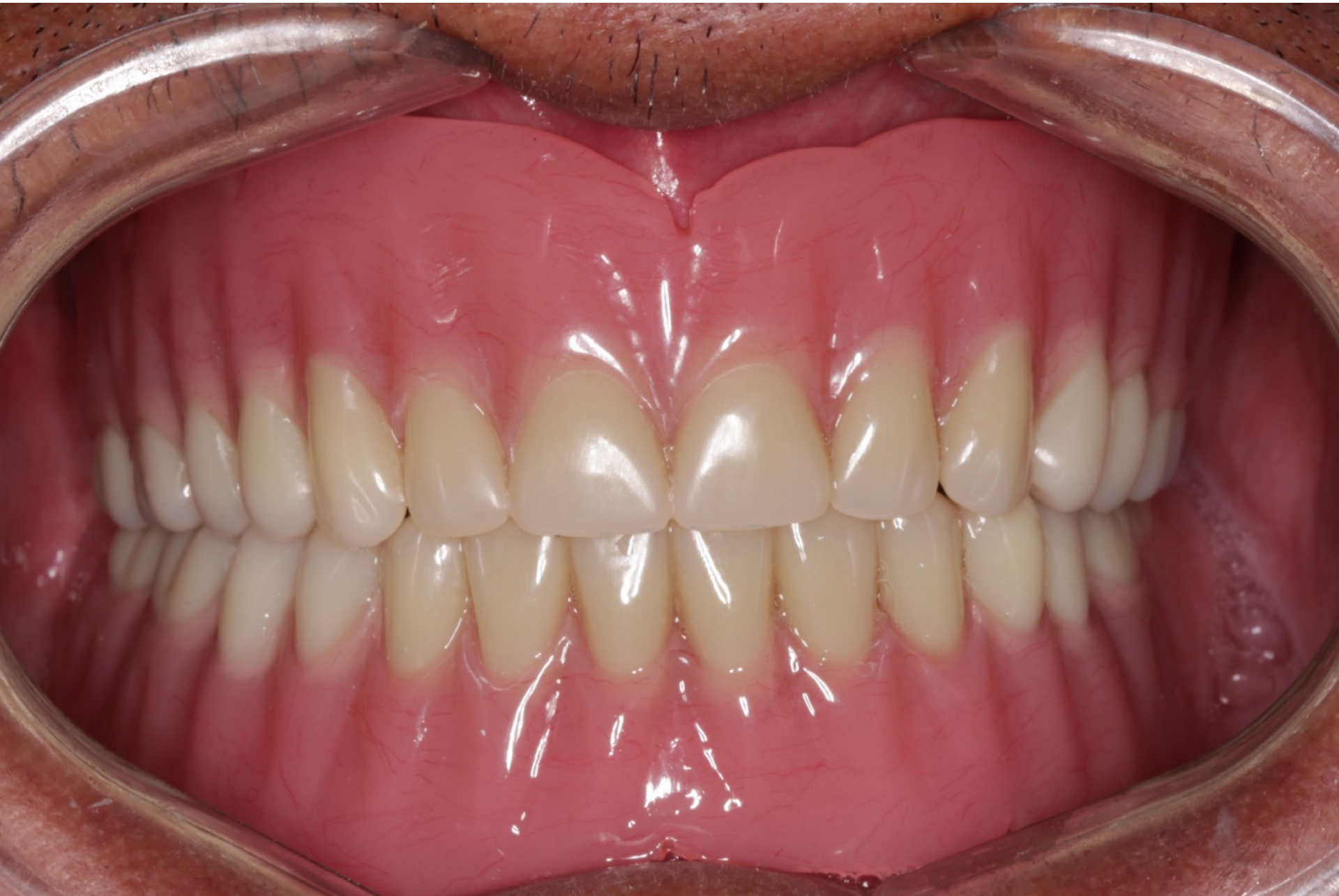

Regular position



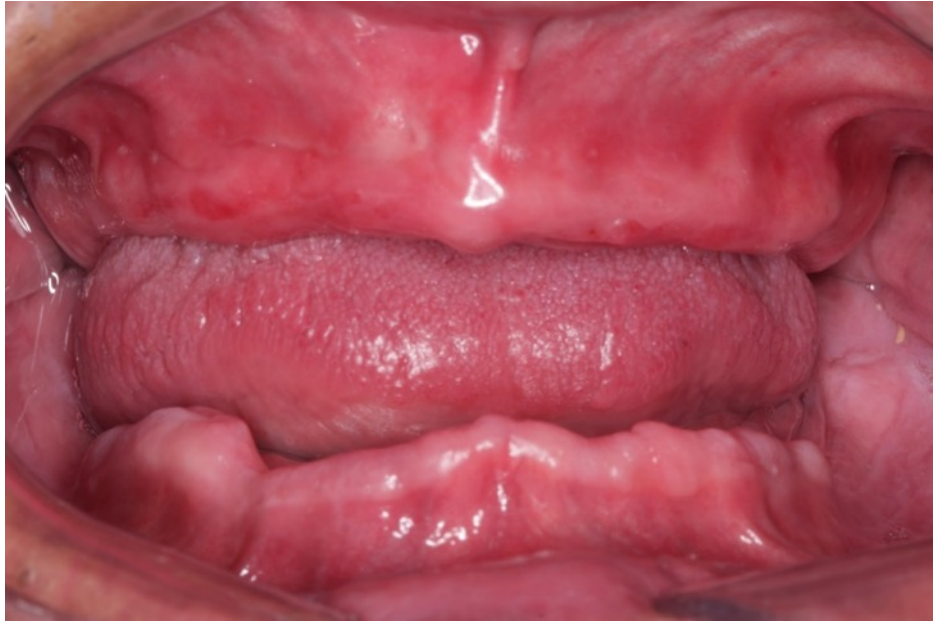Smiling

➤ INSTALATION



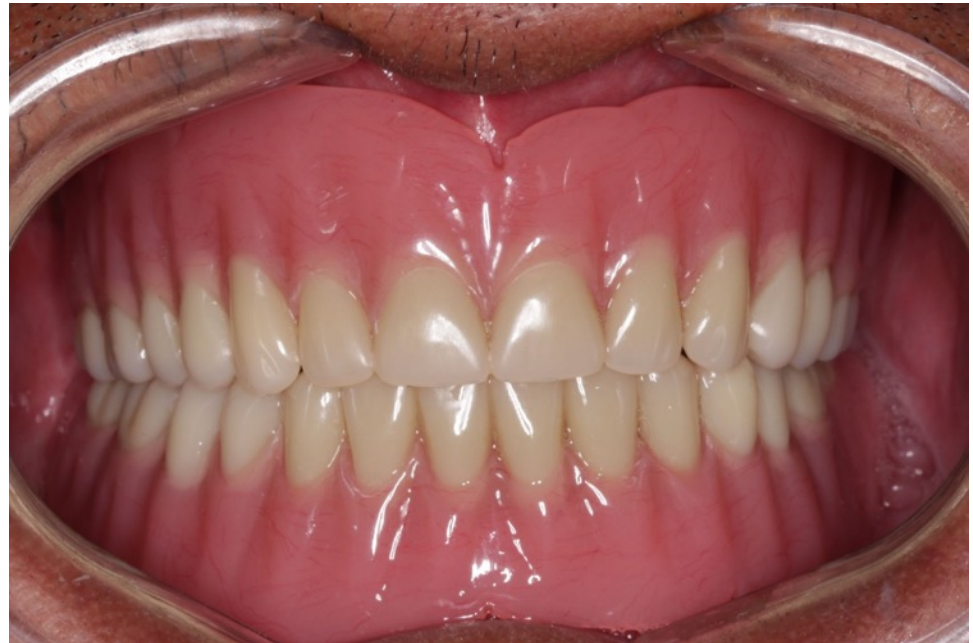➤ INSTALATION





➤ BEFORE

➤ AFTER



WITHOUT DENTURE

WITH DENTURE



WITHOUT DENTURE



WITH DENTURE





**Secours Dentaire
International**

Dental-Aid International