

## CASE 06

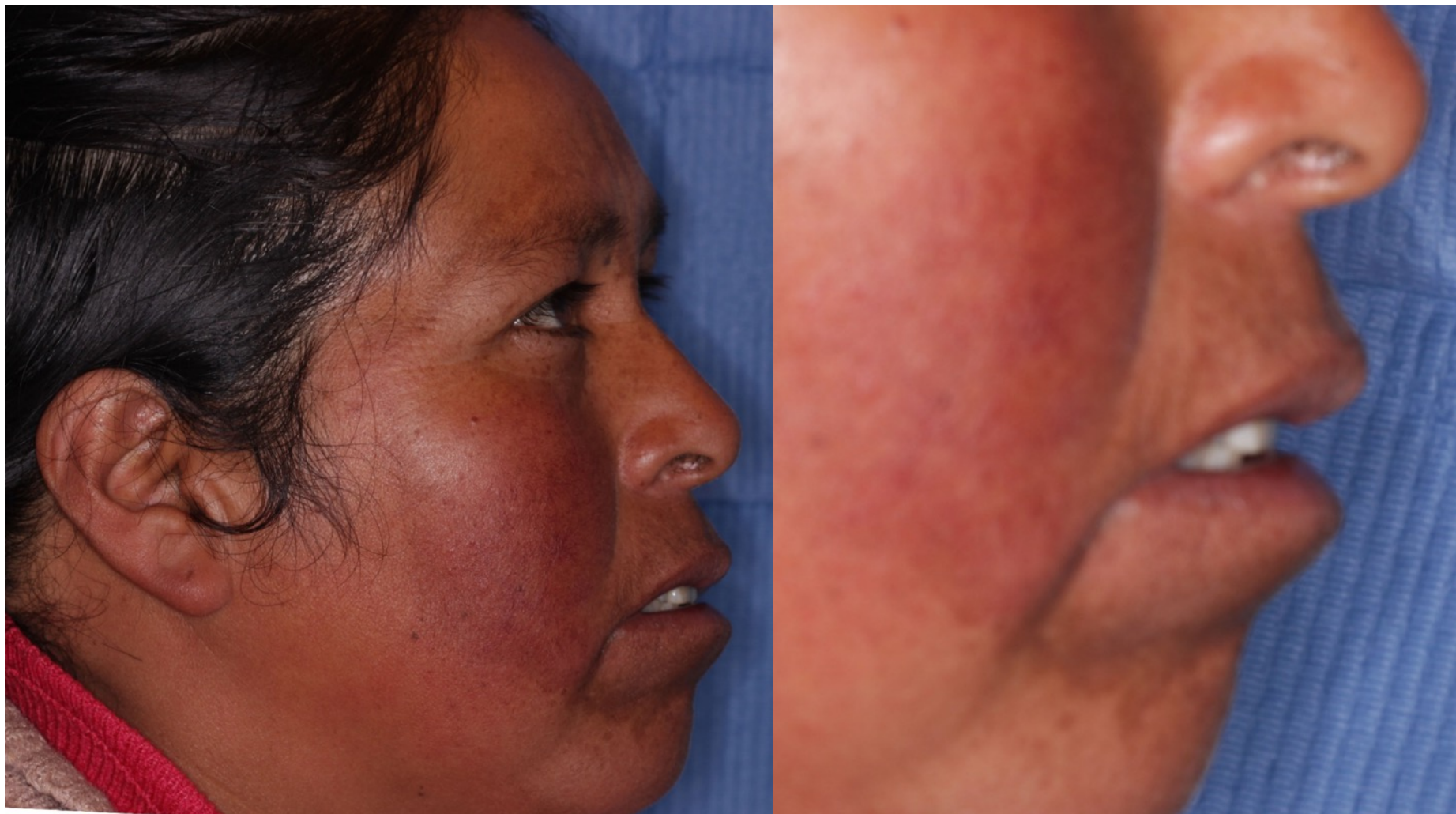### GENERAL INFORMATION:

- **Sex:** Femenino
- **Age:** 46
- **Address:** Pacchanta, Ocongate - Cusco
- **Occupation:** Home

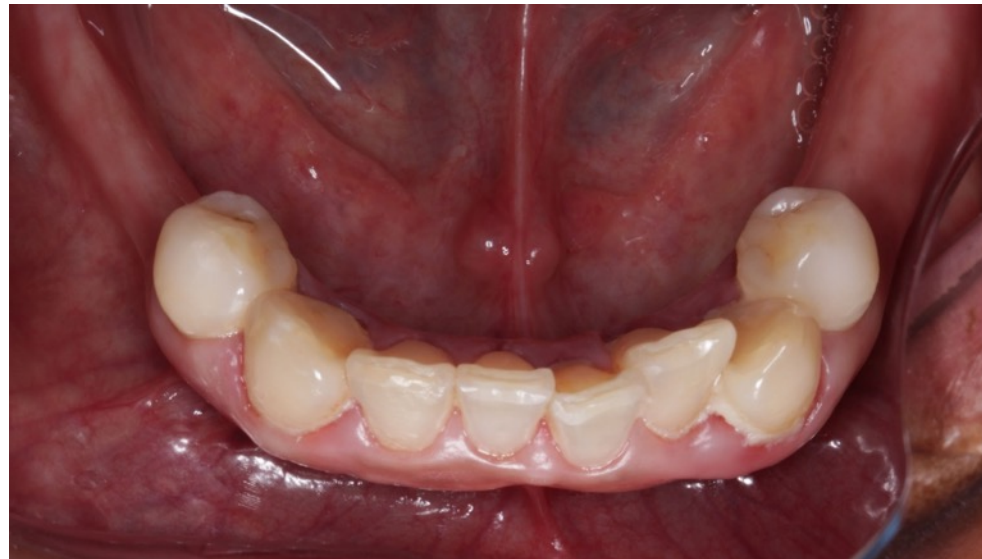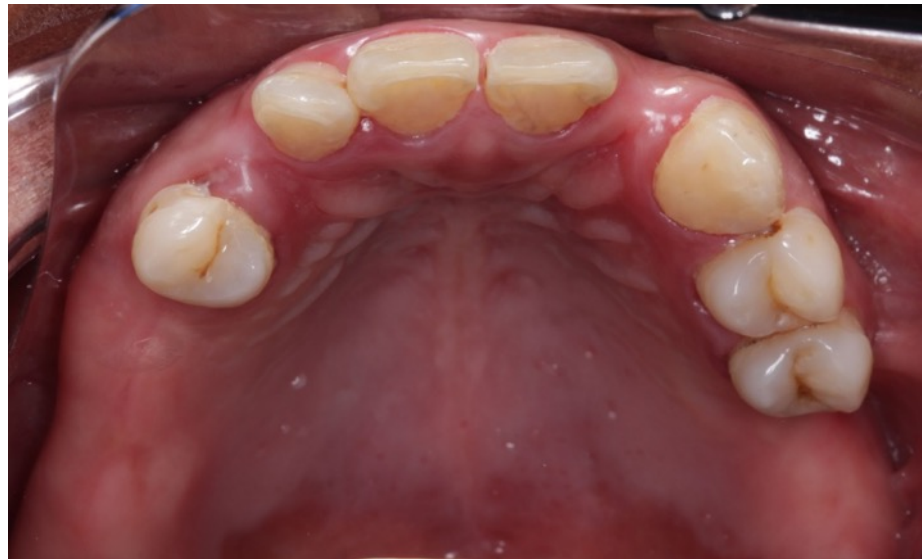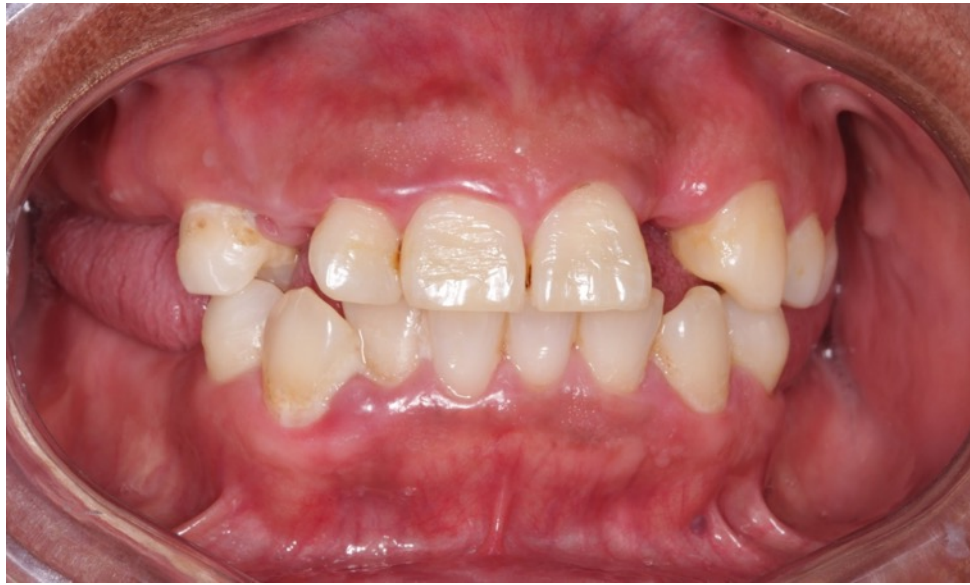# EXTRAORAL EXAM - FRONTAL



# EXTRAORAL EXAM - PROFILE

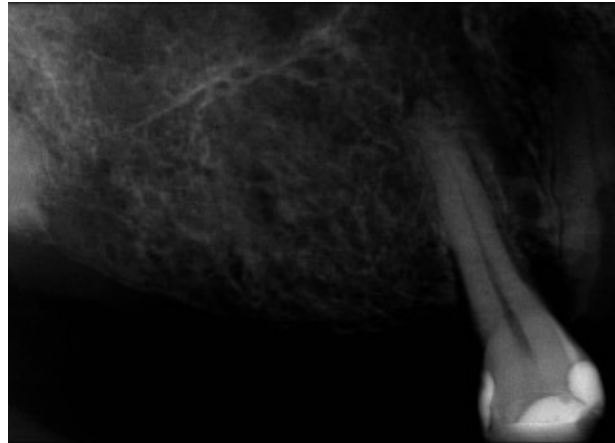


# INTRORAL EXAM

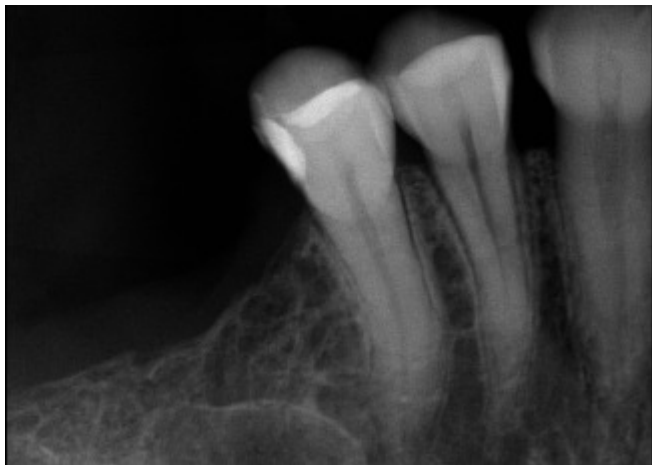
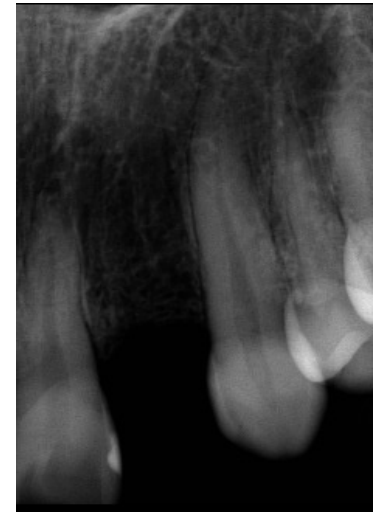
# X-RAYS & ODONTOGRAM

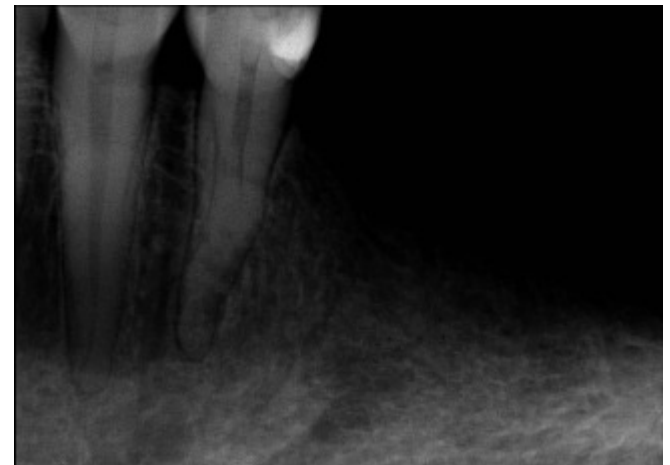
Tooth 1.4



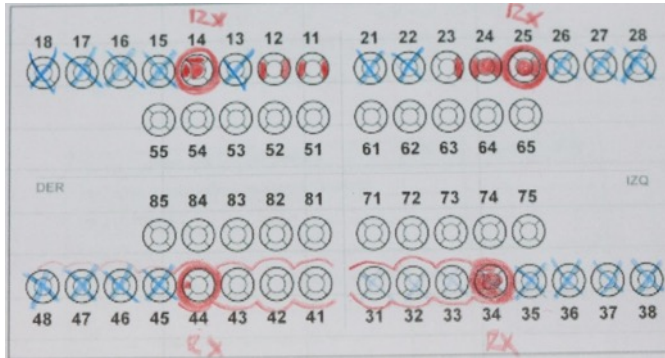
Tooth 2.3 – 2.4



Tooth 4.4



Tooth 3.4



## DIAGNOSIS

- **Gingivitis associated to plaque**
- **Dentin caries**
- **Partial bimaxillary edentulous**

## TREATMENT PLAN

- **Dental cleaning**
- **Fillings**
- **Bimaxillary dentures**

# CLINICAL PROTOCOL

# CLINICAL PROTOCOL

## 1<sup>st</sup> session

- Clinical exam
- Primary impressions
- Cast model parallelization
- Customized trays elaboration

## 2<sup>nd</sup> session

- Biostatic preparation
- Definitive impressions

## 3<sup>rd</sup> session

- Metal structure try in
- Intermaxillary registration
- Articulation in articulator
- Artificial teeth selection

# CLINICAL PROTOCOL

4<sup>th</sup>  
session

- Teeth try in

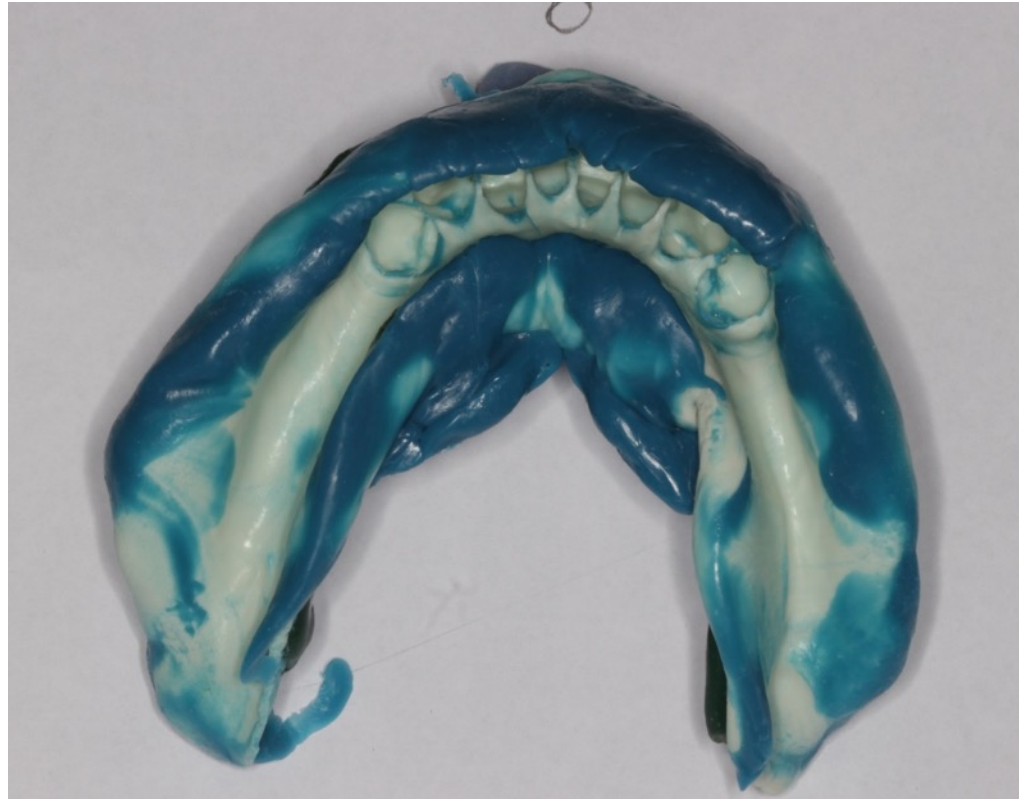
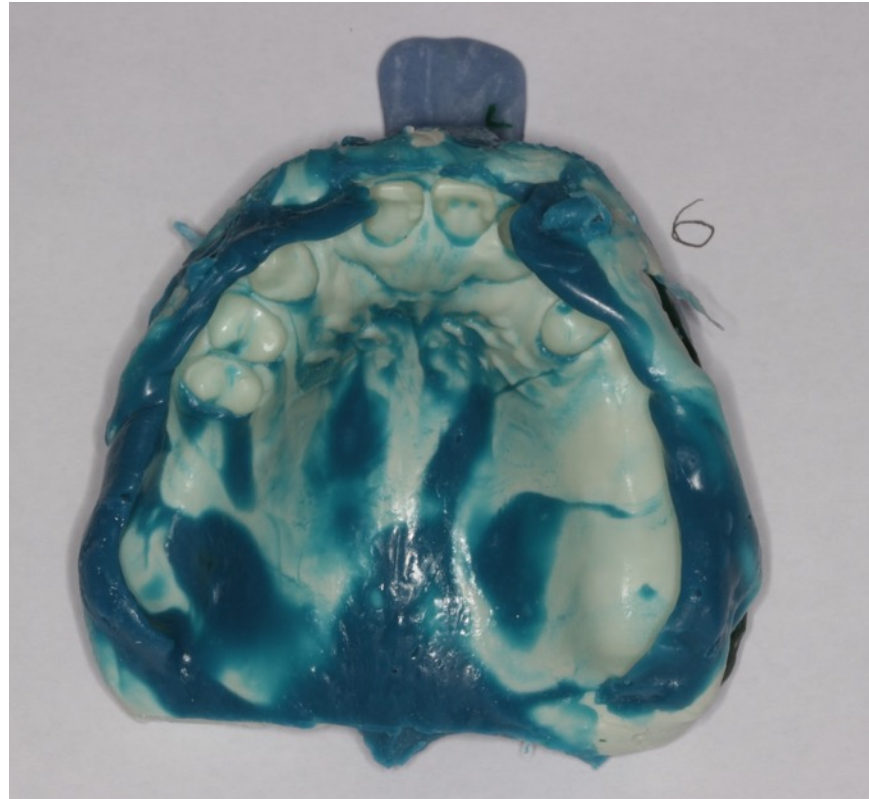
5<sup>th</sup>  
session

- Installation

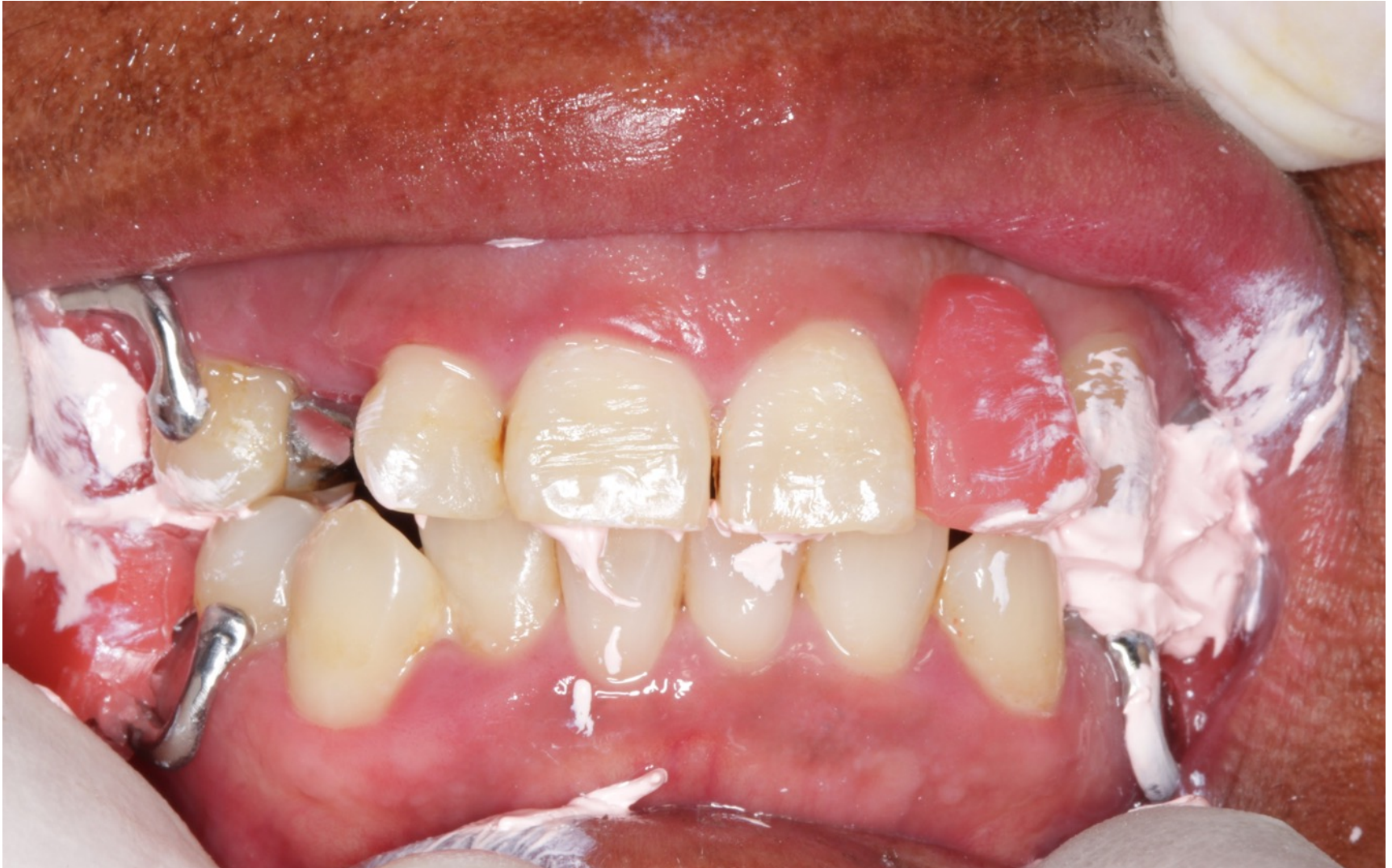6<sup>th</sup>  
session

- Follow up

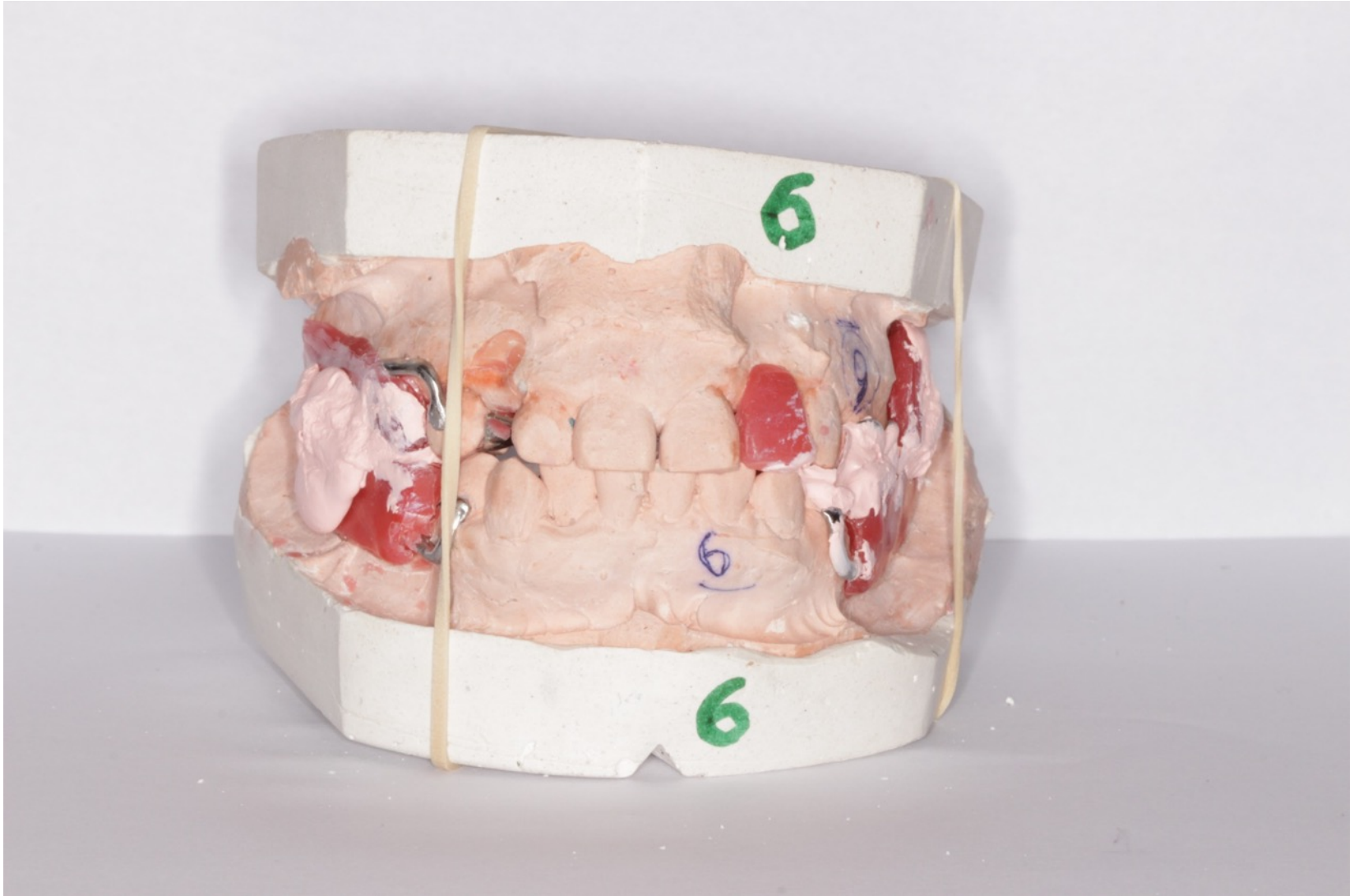
# ➤ DEFINITIVE IMPRESSION



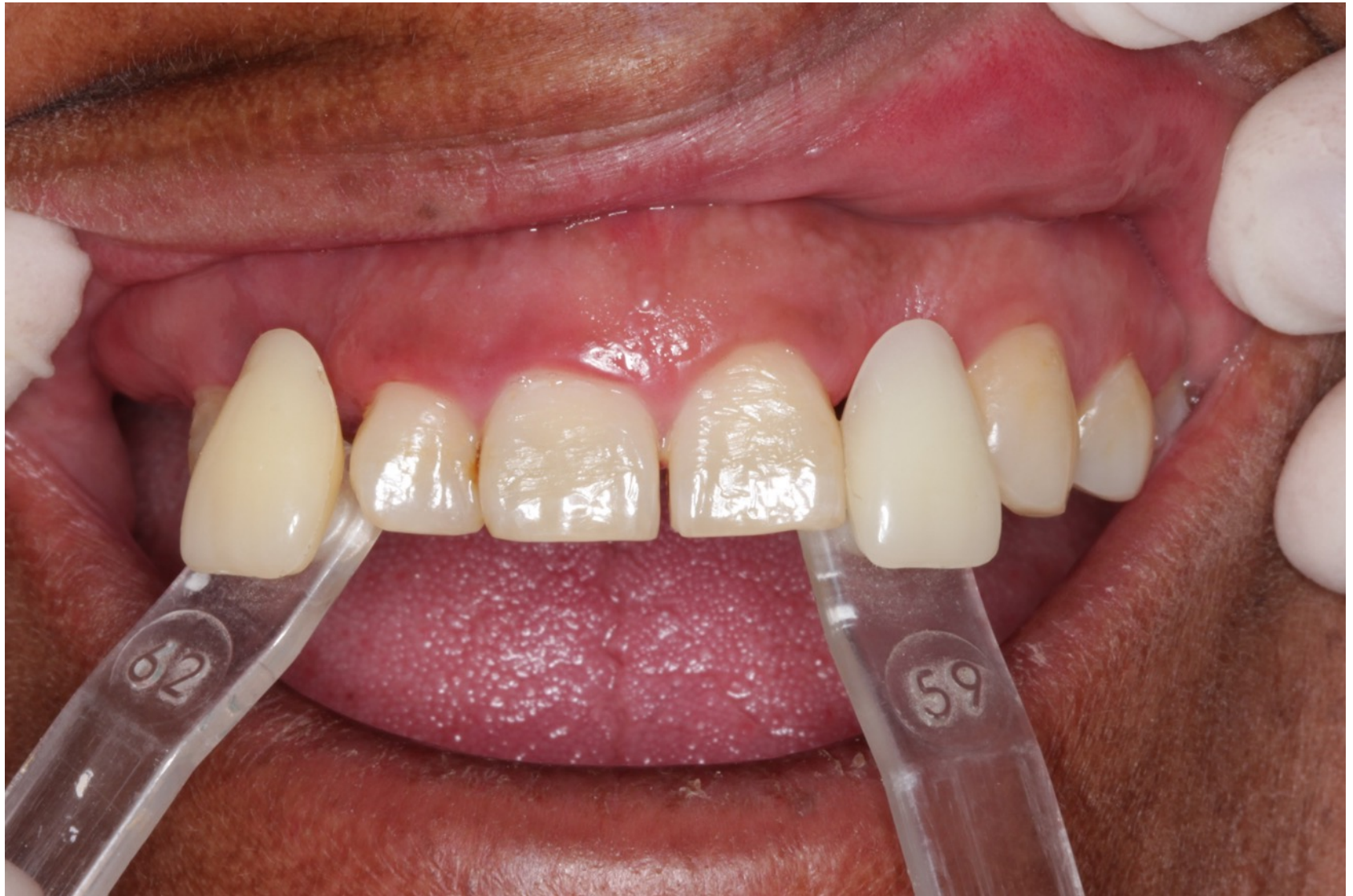➤ METAL TRY IN AND INTERMAXILLARY  
REGISTRATION



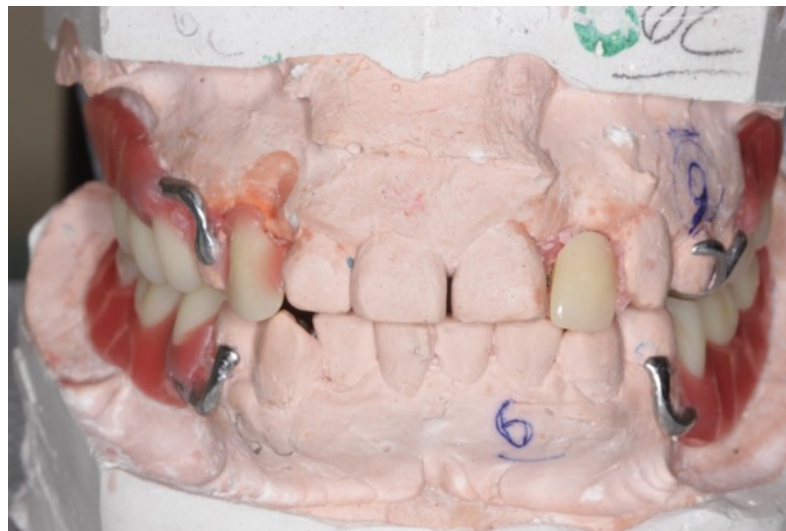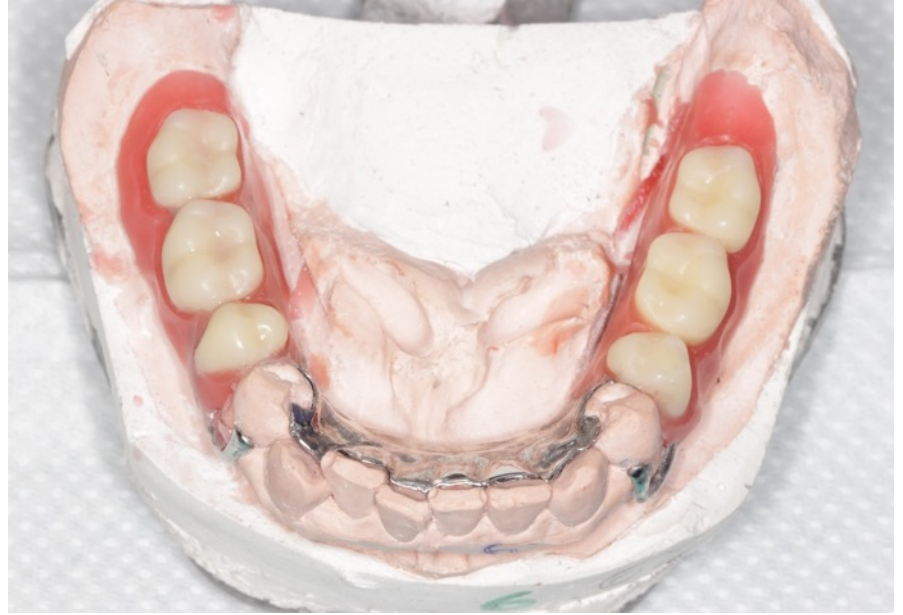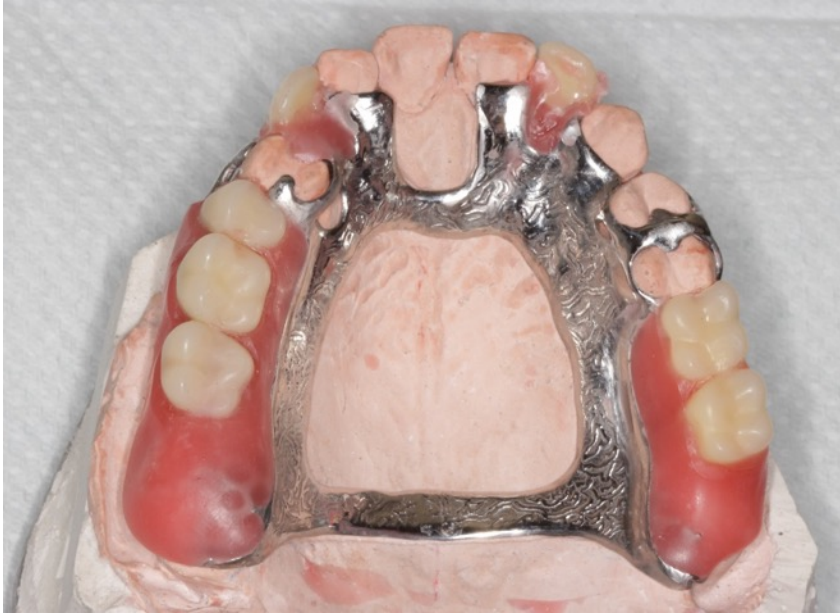# ➤ INTERMAXILLARY REGISTRATION



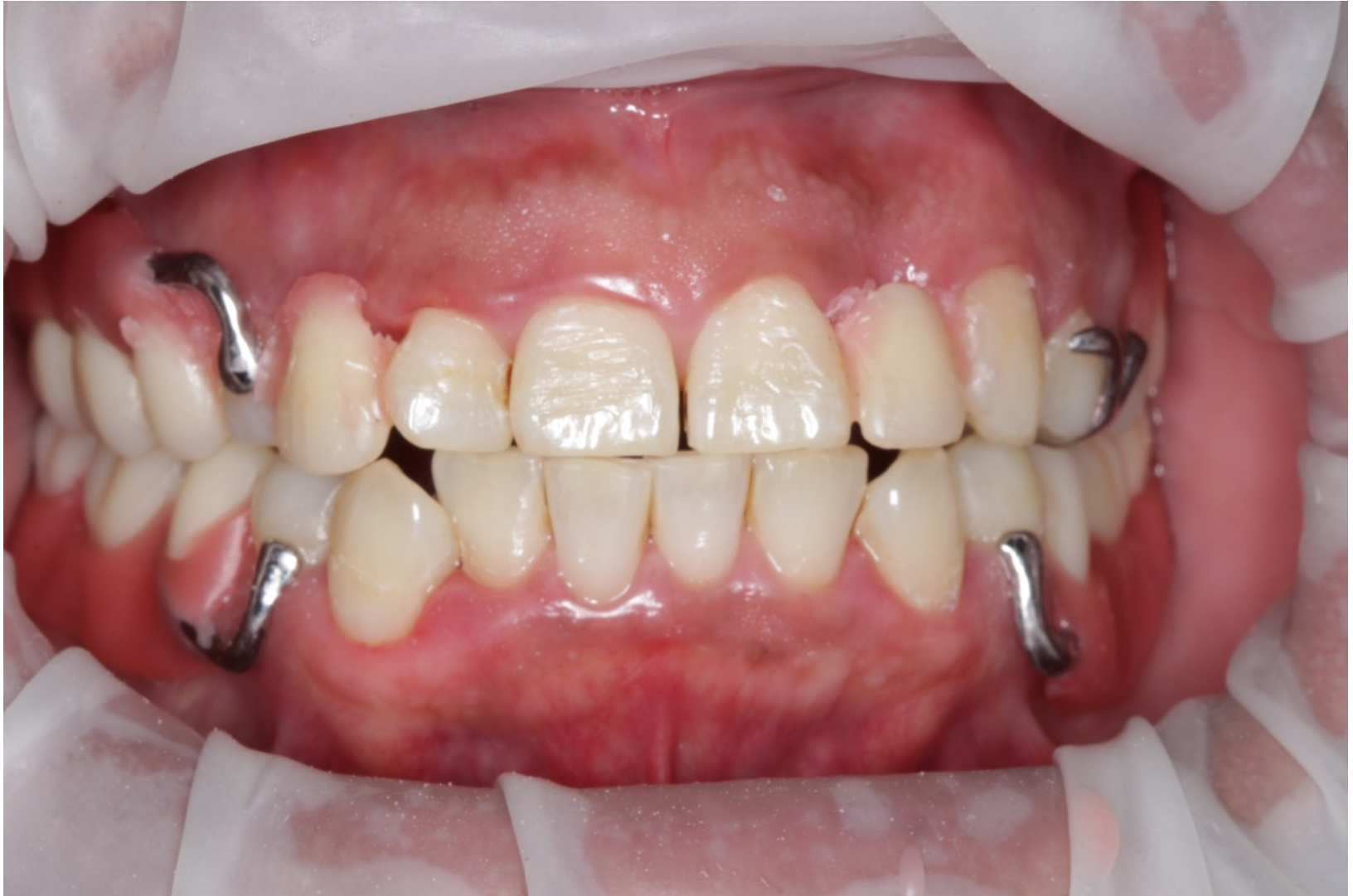# ➤ TEETH SELECTION



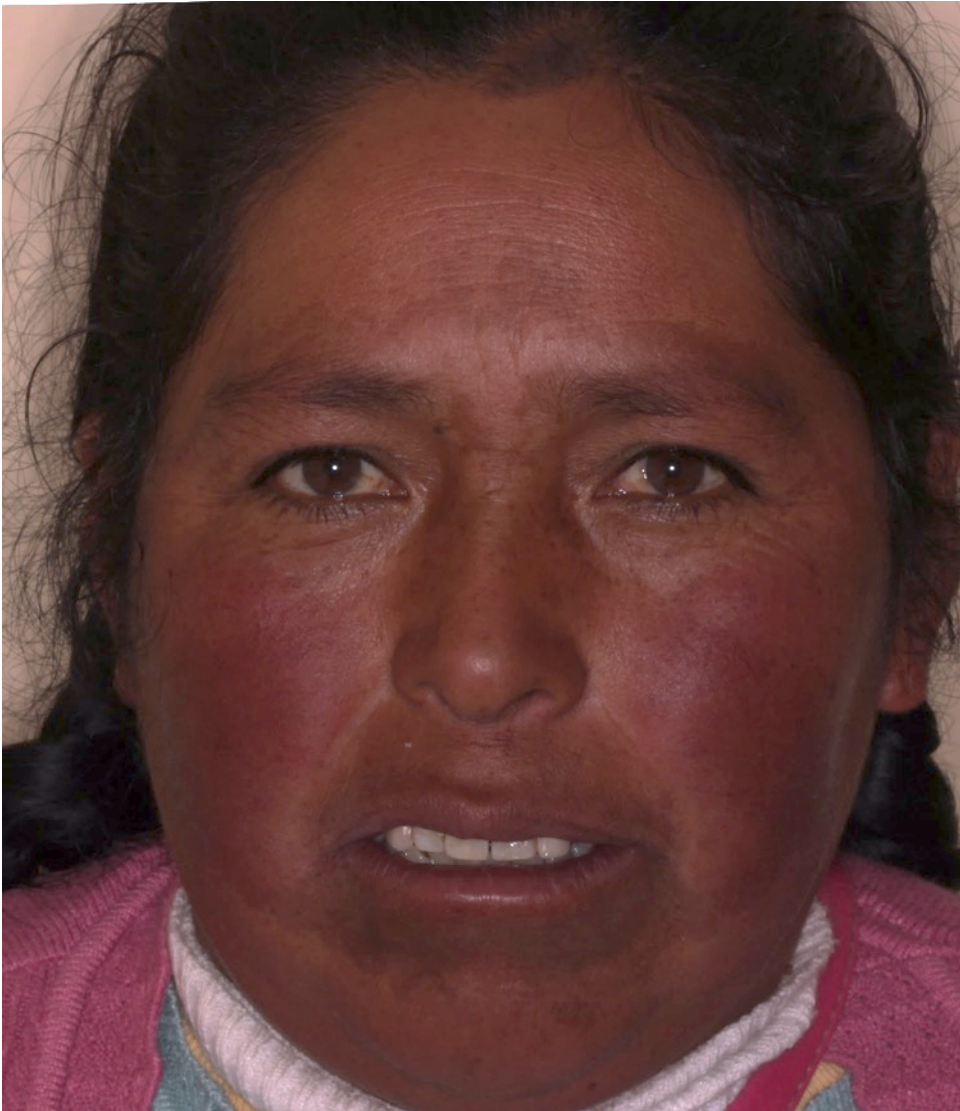# ➤ TEETH IN WAX



# ➤ TEETH TRY IN



# ➤ TEETH TRY IN

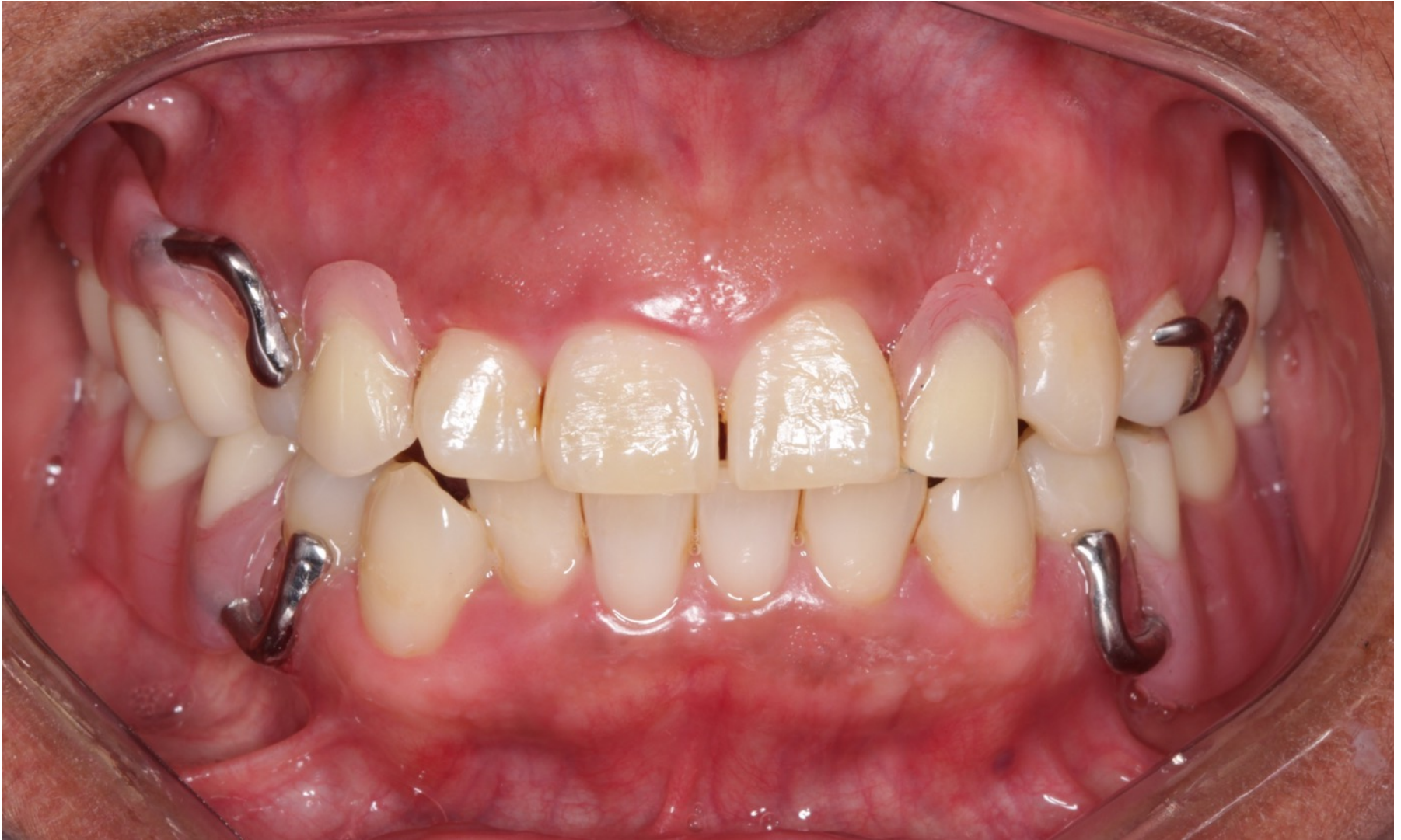

Regular position



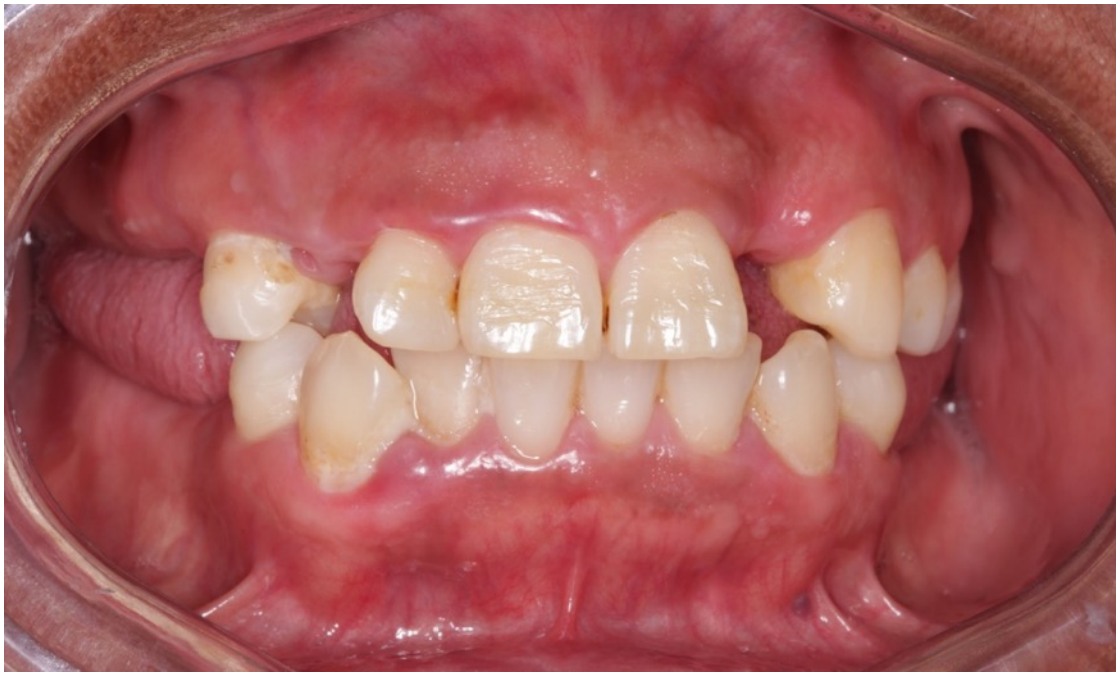Smiling

# ➤ INSTALLATION



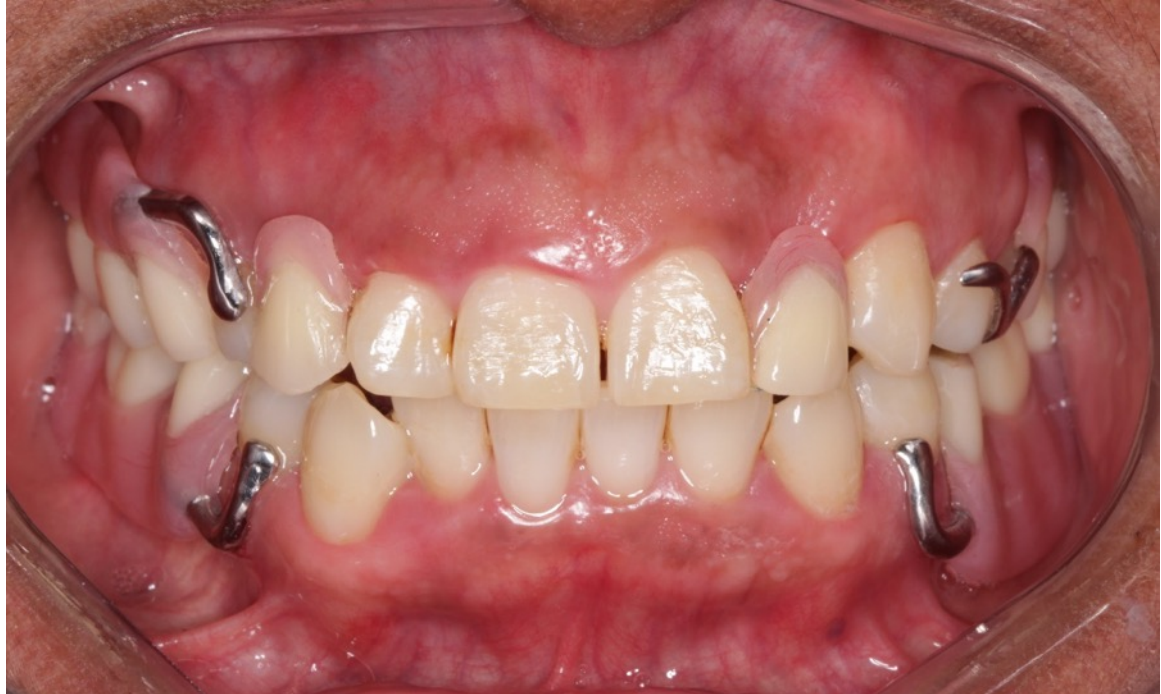# ➤ INSTALLATION





➤ BEFORE

➤ AFTER



➤ BEFORE



➤ AFTER





**Secours Dentaire  
International**

Dental-Aid International