

CASE 08

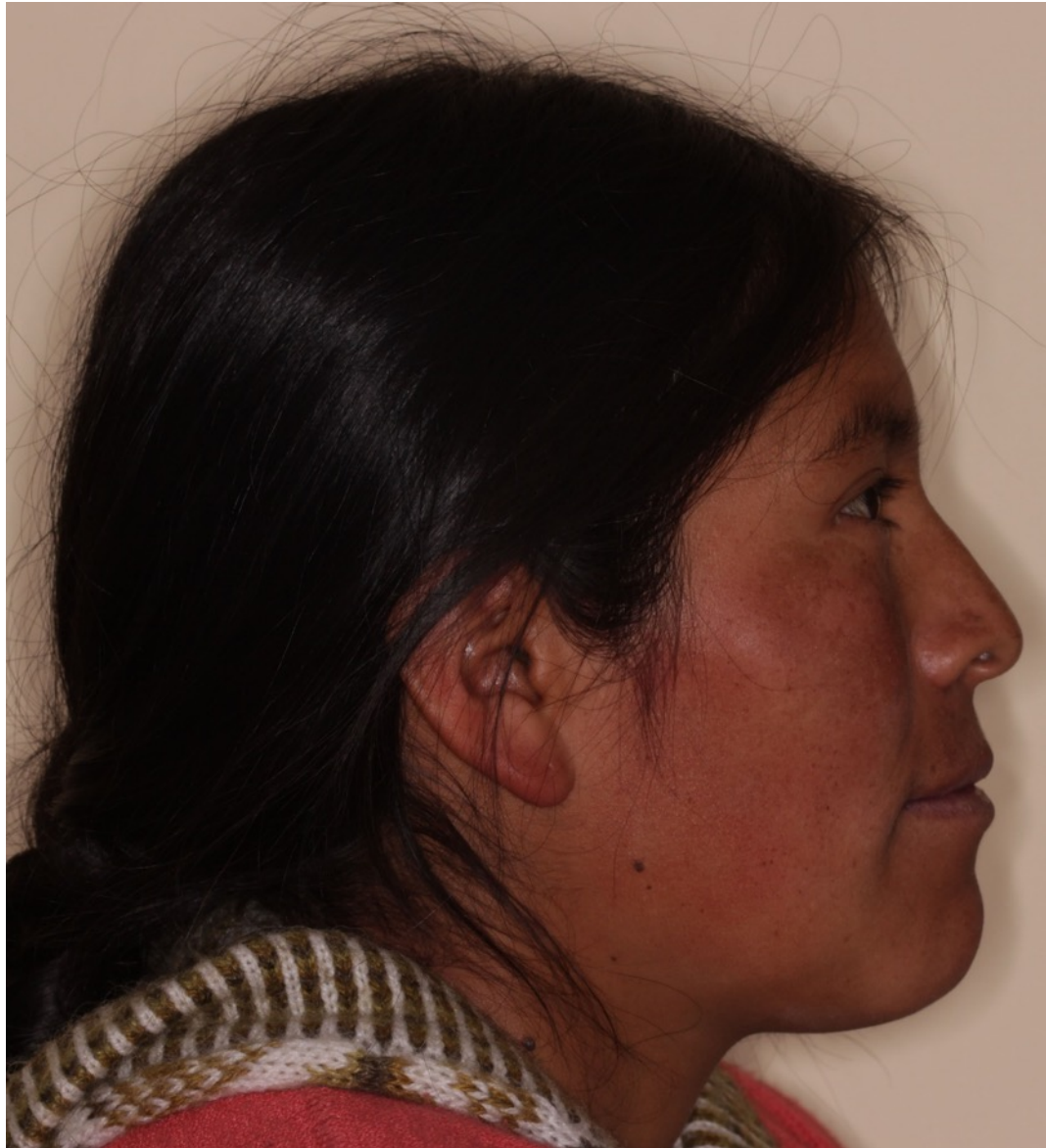
GENERAL INFORMATION:

- **Sex:** Female
- **Age:** 31
- **Address:** Pacchanta - Ocongate
- **Occupation:** Home

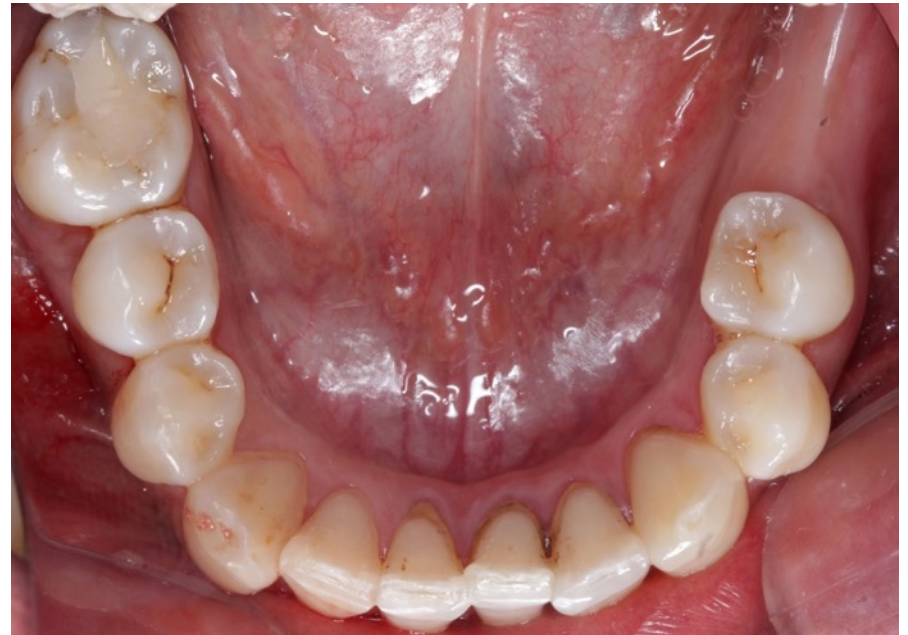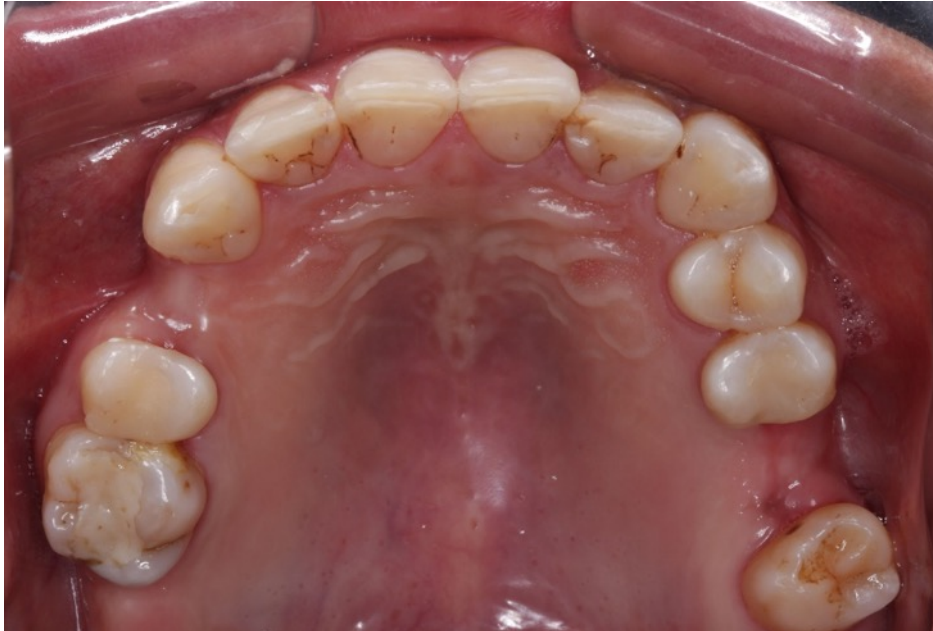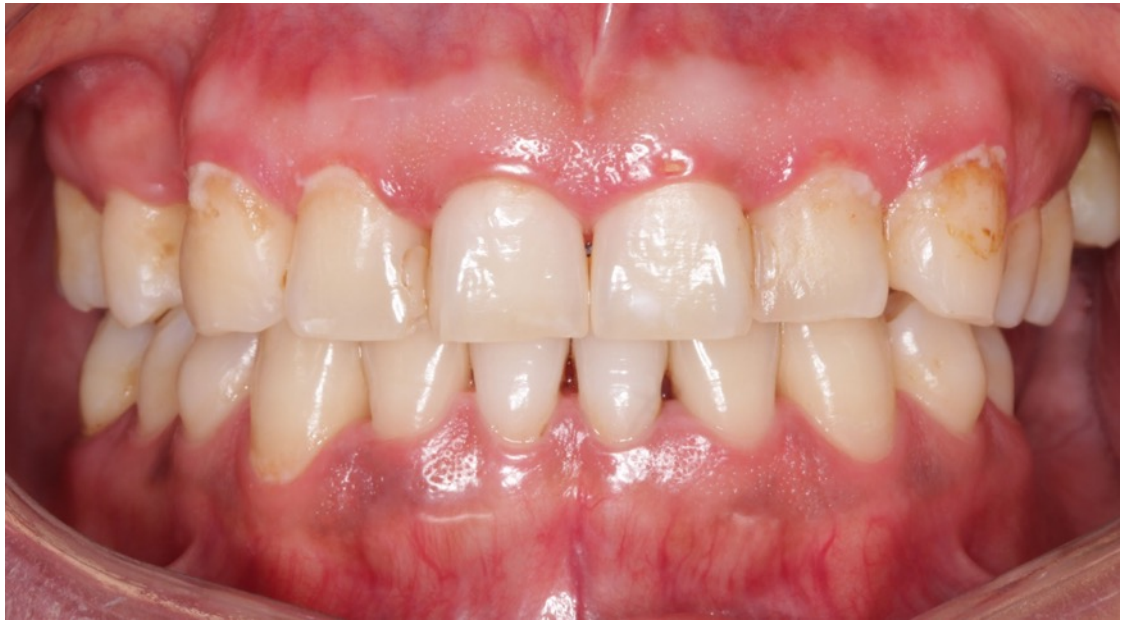EXTRAORAL EXAM - FRONTAL



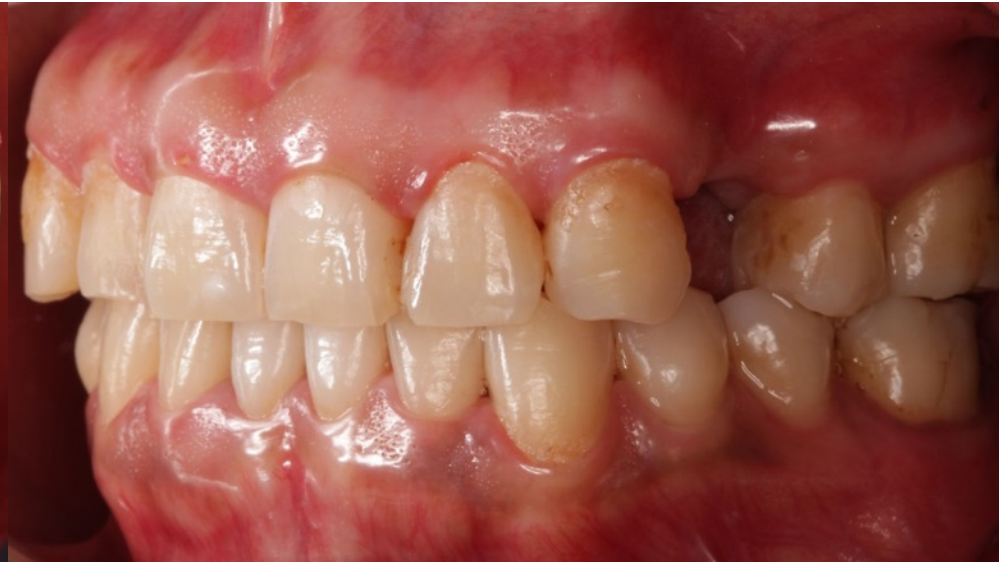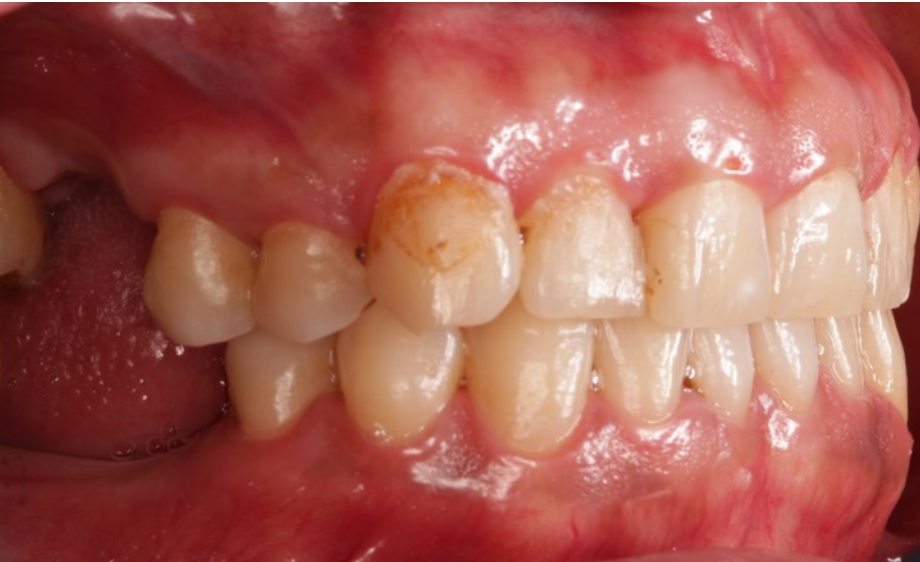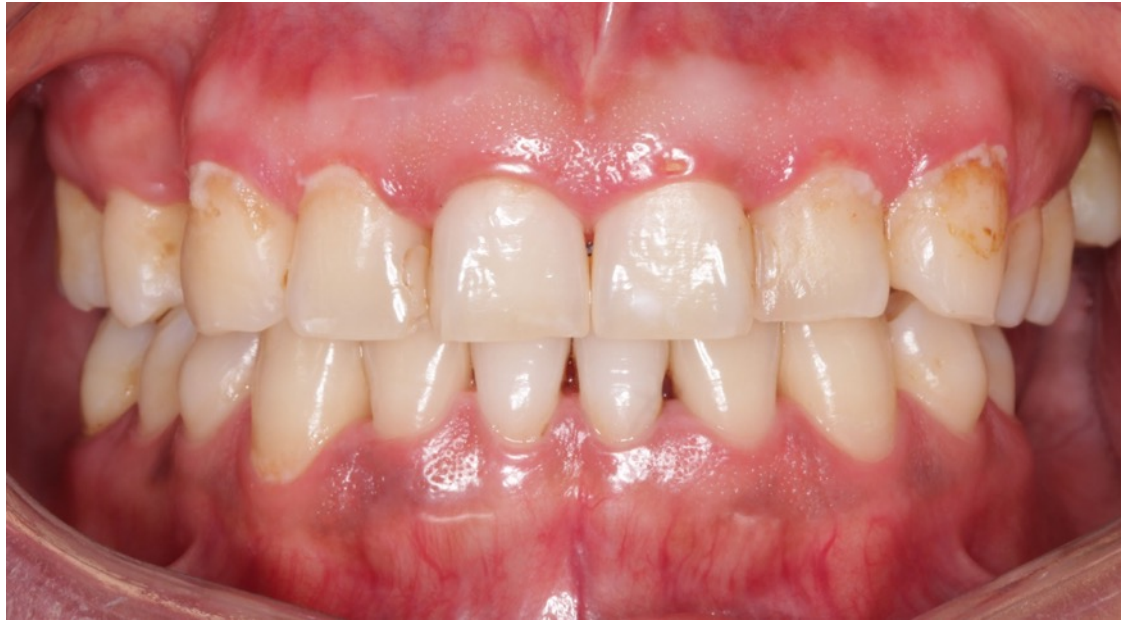EXTRAORAL EXAM - PROFILE




Intraoral exam



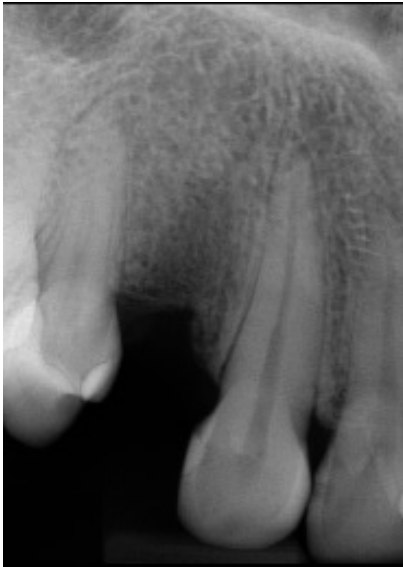Intraoral exam



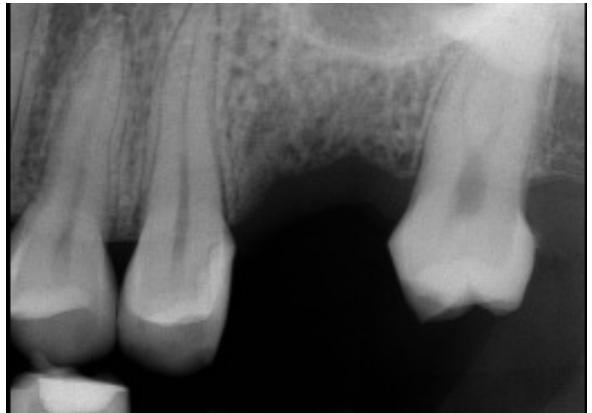

X-RAYS & ODONTOGRAM

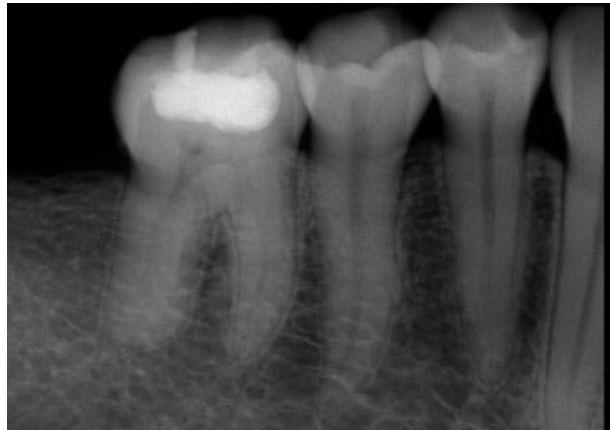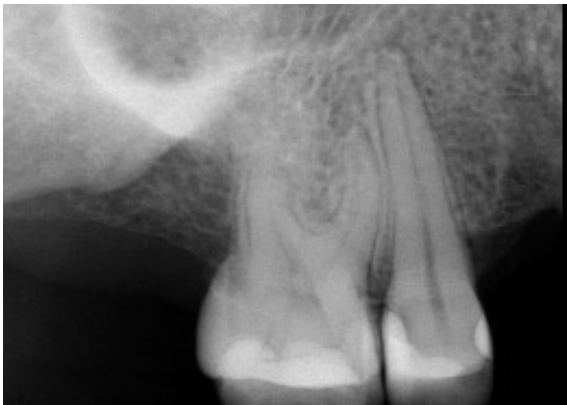Pieza 1.3



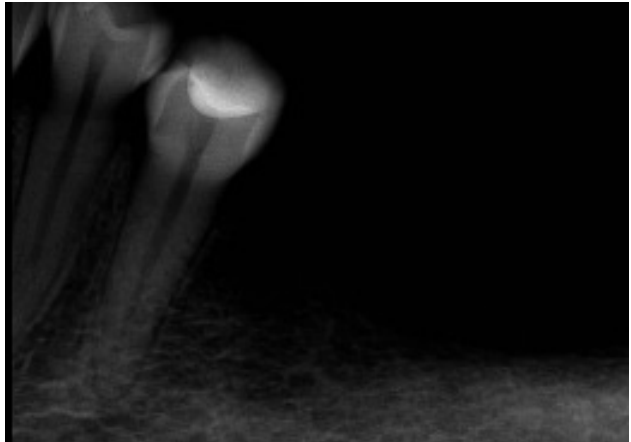
Pieza 25, 2.7



Pieza 1.6 – 1.5



Pieza 4.6



Pieza 3.5

DIAGNOSIS

- Gingivitis associated with plaque
- Dentin caries
- Partial bimaxillary edentulous

TREATMENT

- Dental cleaning
- Fillings
- Bimaxillary dentures

CLINICAL PROTOCOL

CLINICAL PROTOCOL

1st session

- Clinical exam
- Primary impressions
- Cast model parallelization
- Customized trays elaboration

2nd session

- Biostatic preparation
- Definitive impressions

3rd session

- Metal structure try in
- Intermaxillary registration
- Articulation in articulator
- Artificial teeth selection

CLINICAL PROTOCOL

**4th
session**

- Teeth try in

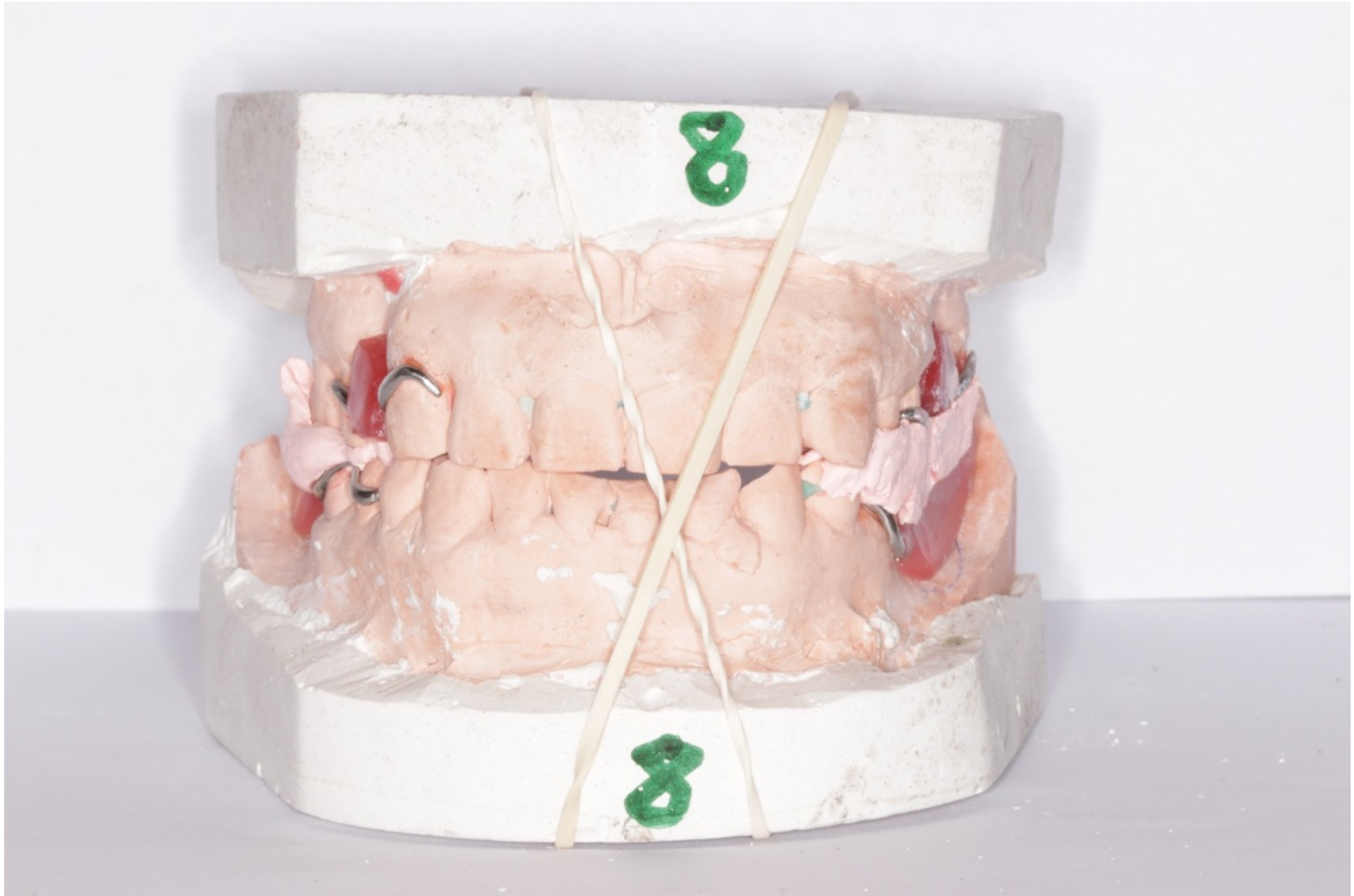**5th
session**

- Installation

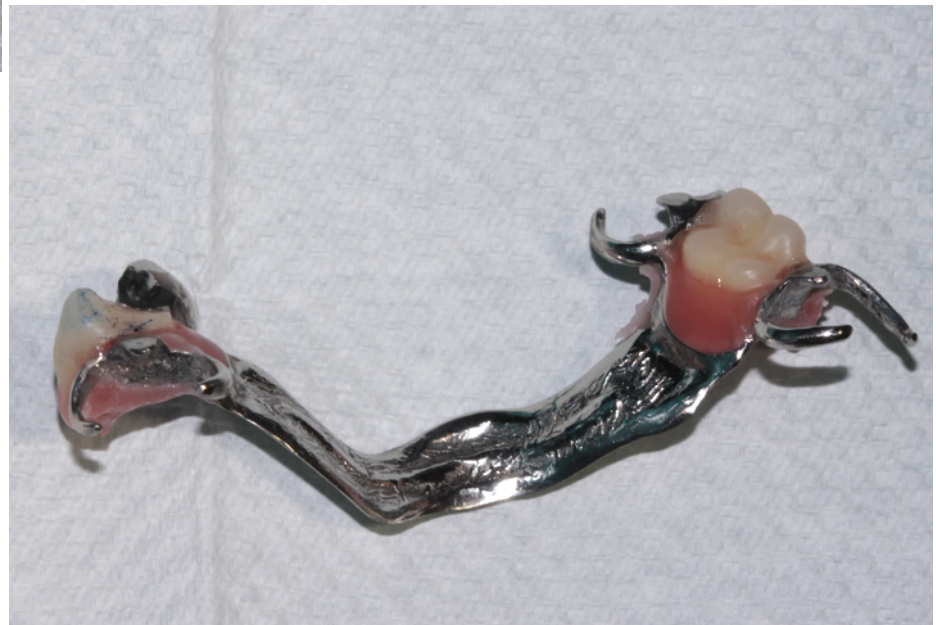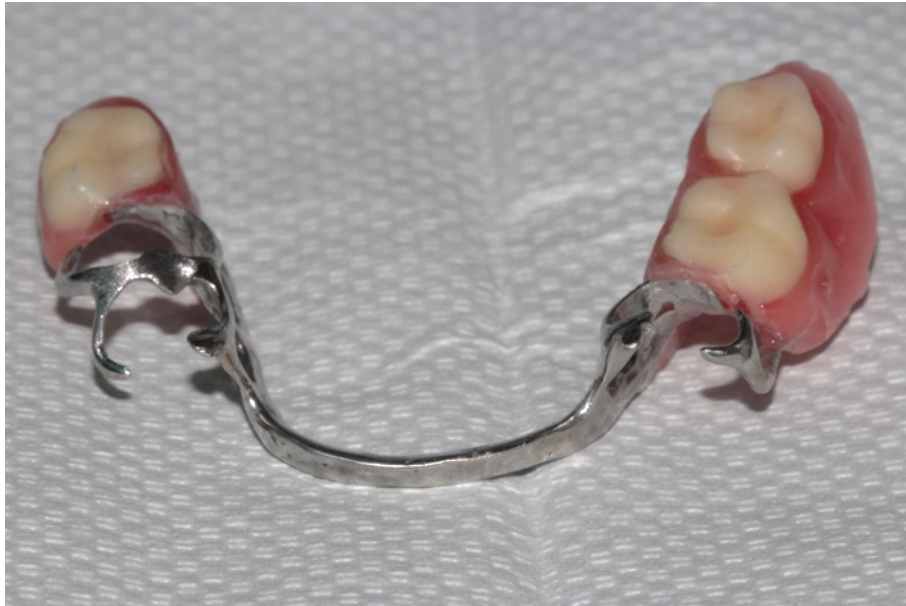**6th
session**

- Follow up

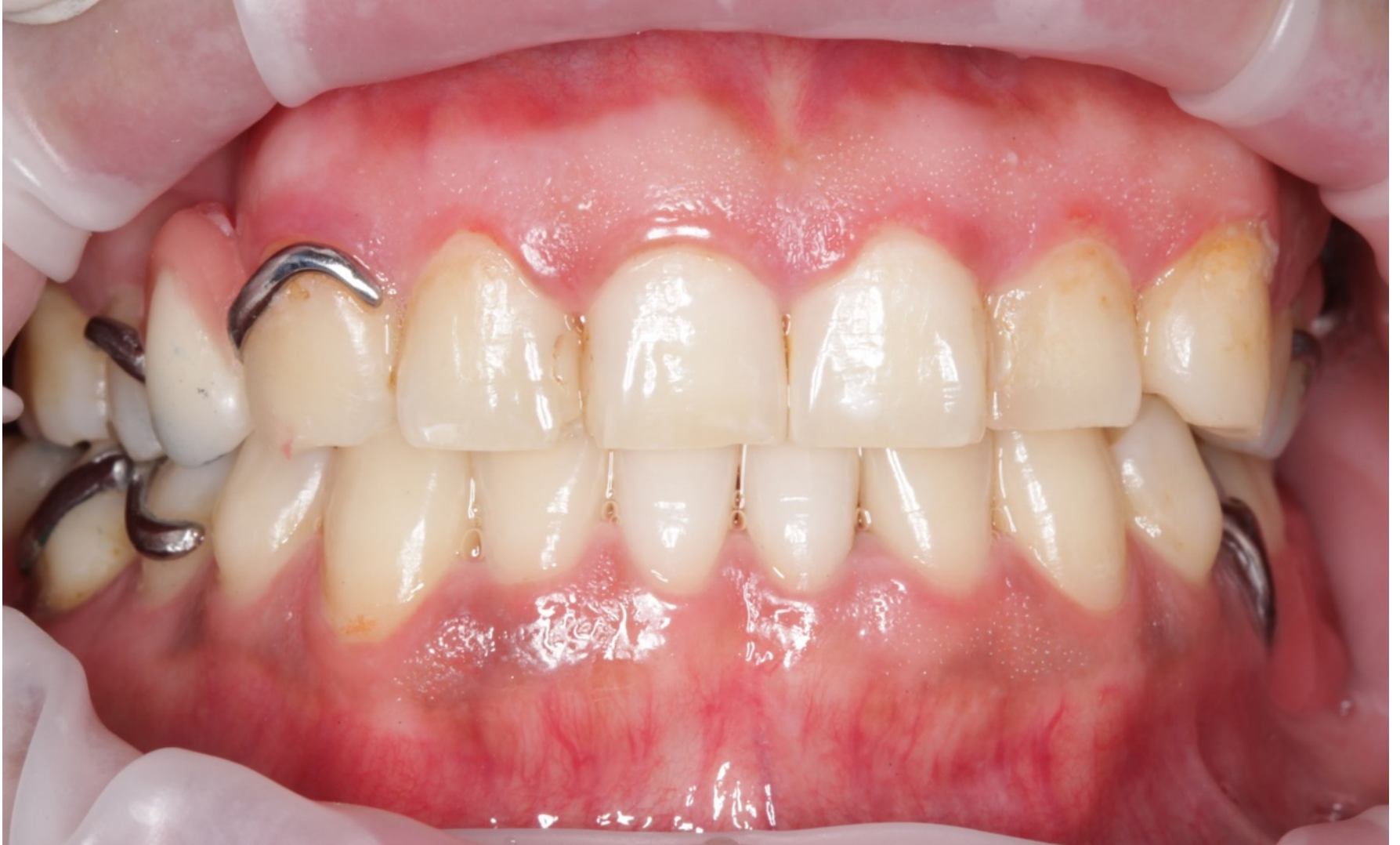➤ INTERMAXILLARY REGISTRATION



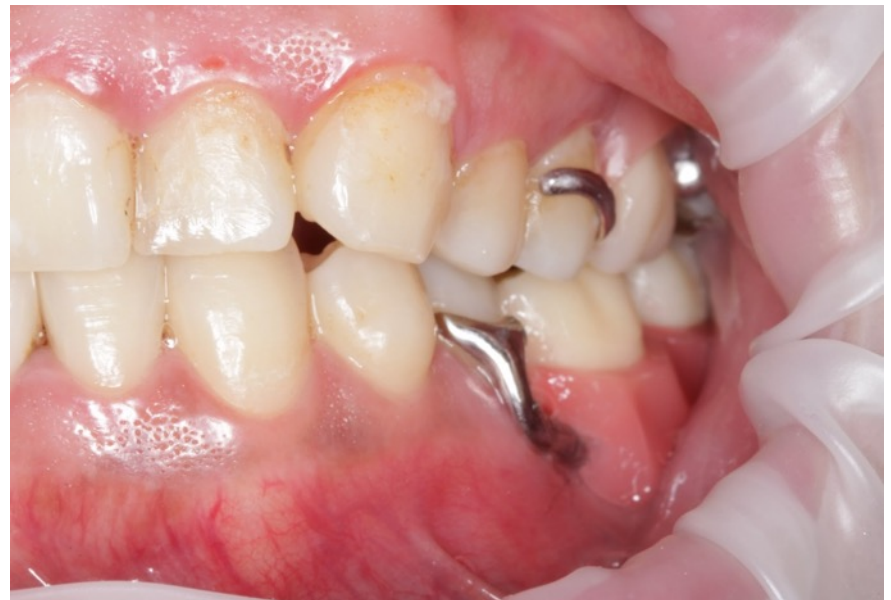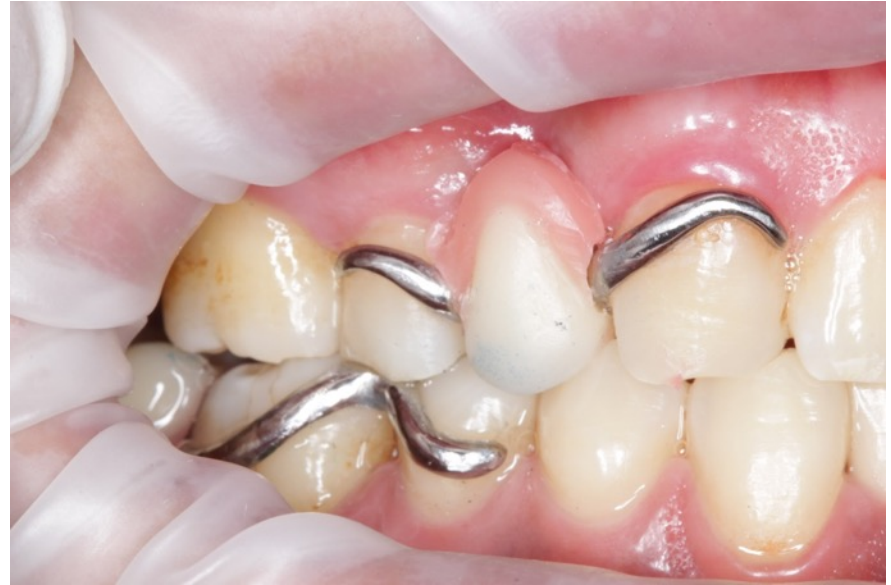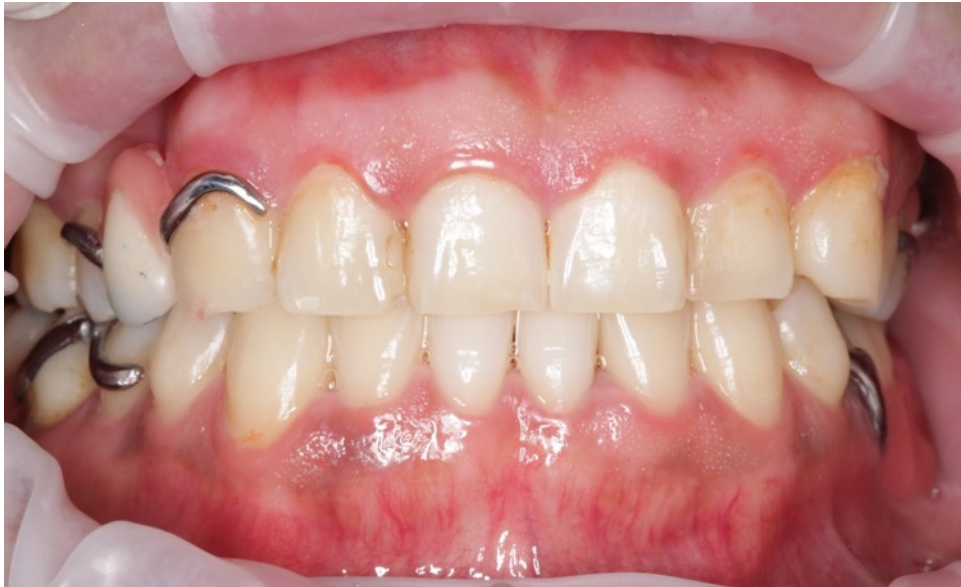➤ TEETH IN WAX



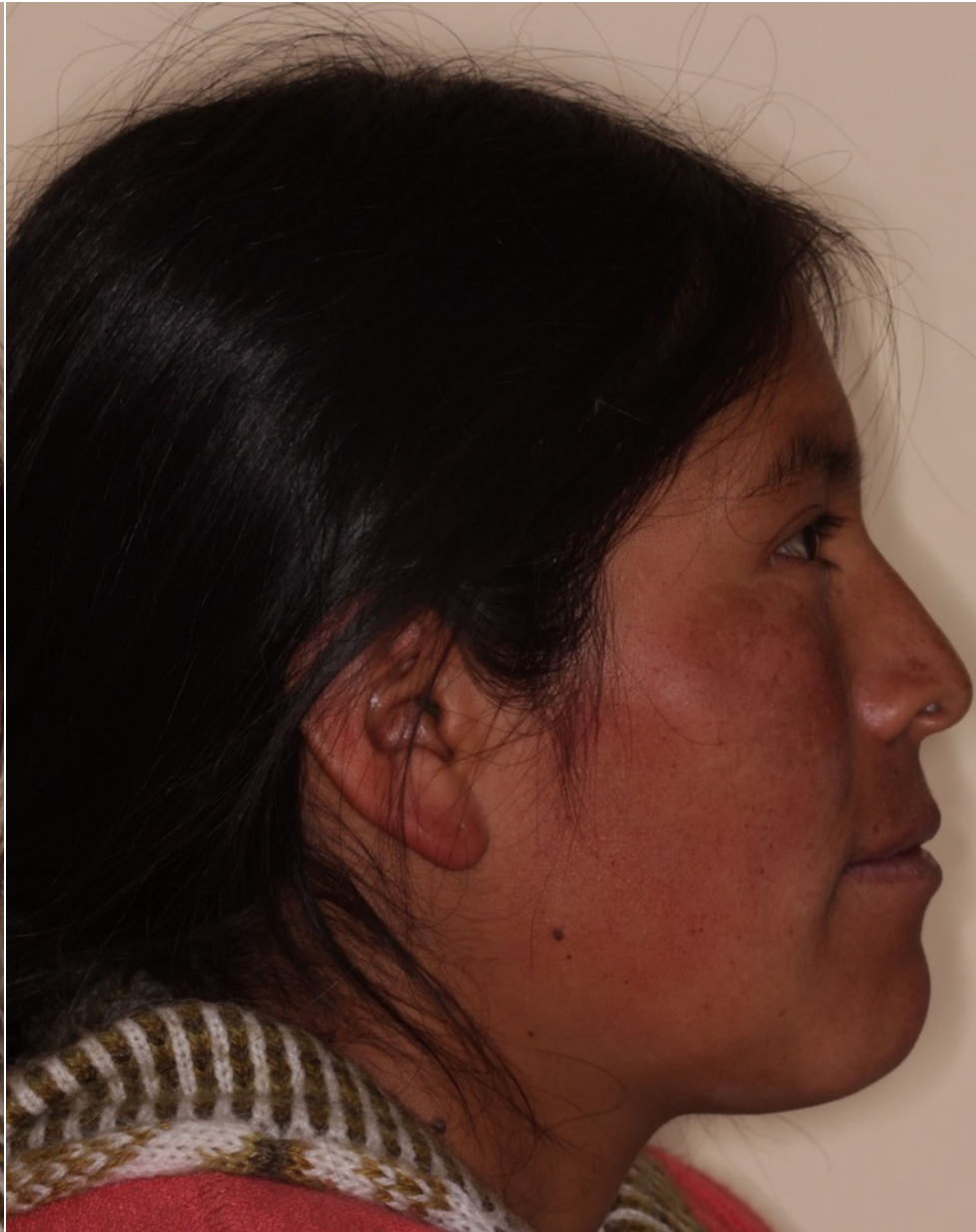
➤ TEETH TRY IN



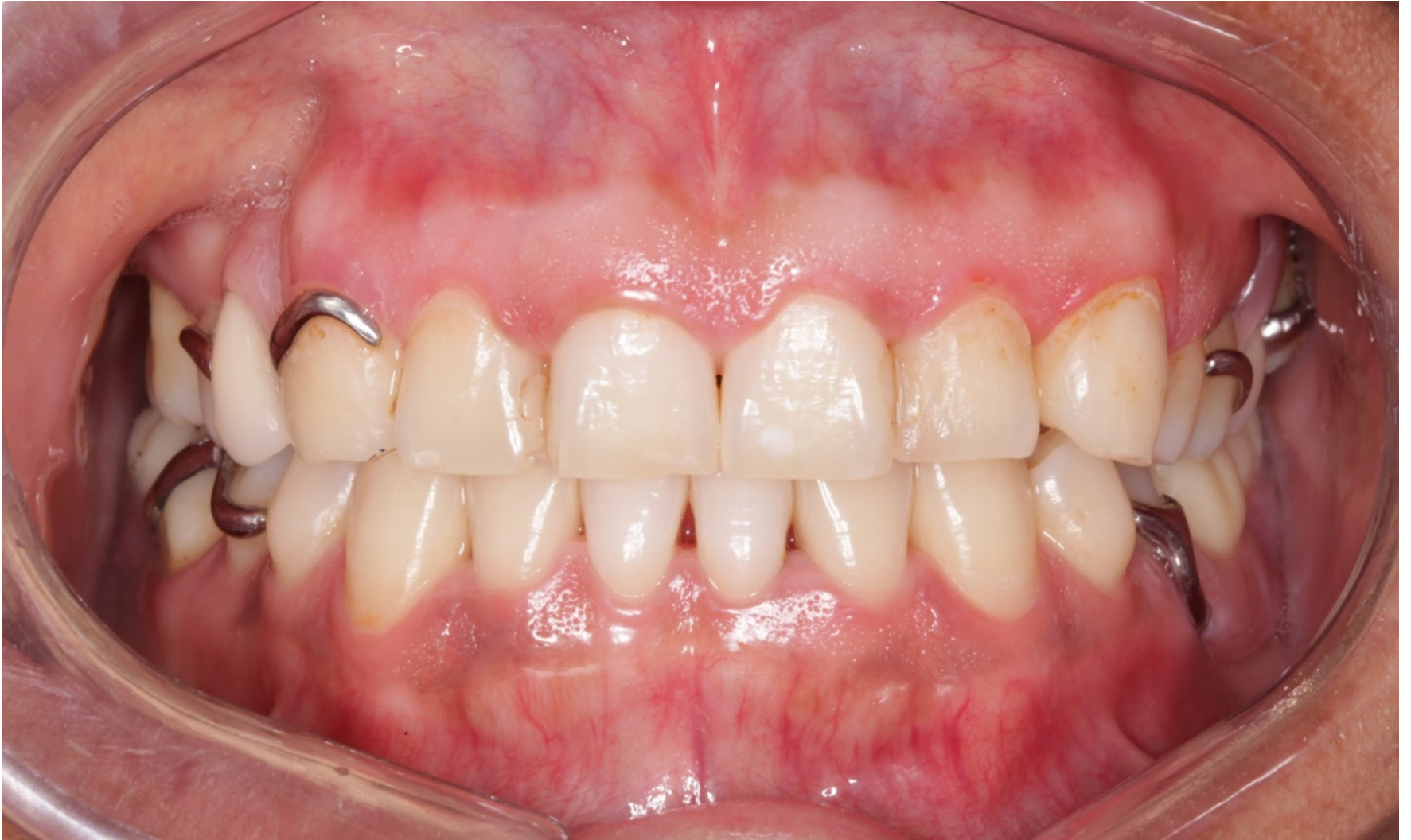➤ TEETH TRY IN



➤ TEETH TRY IN

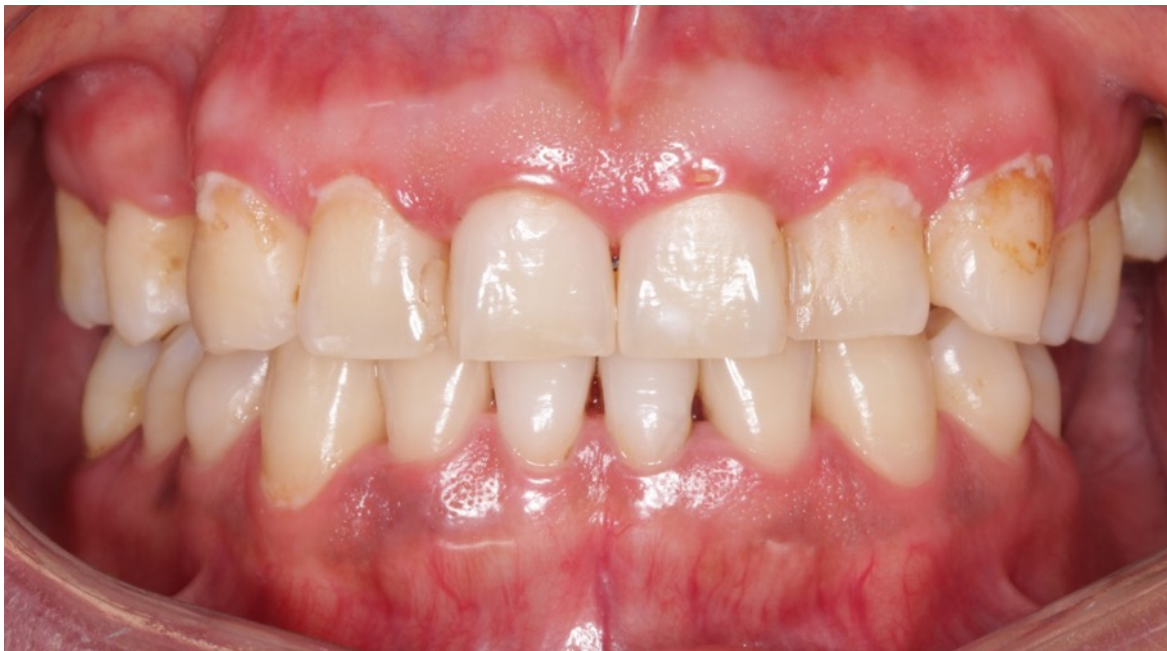

➤ INSTALLATION



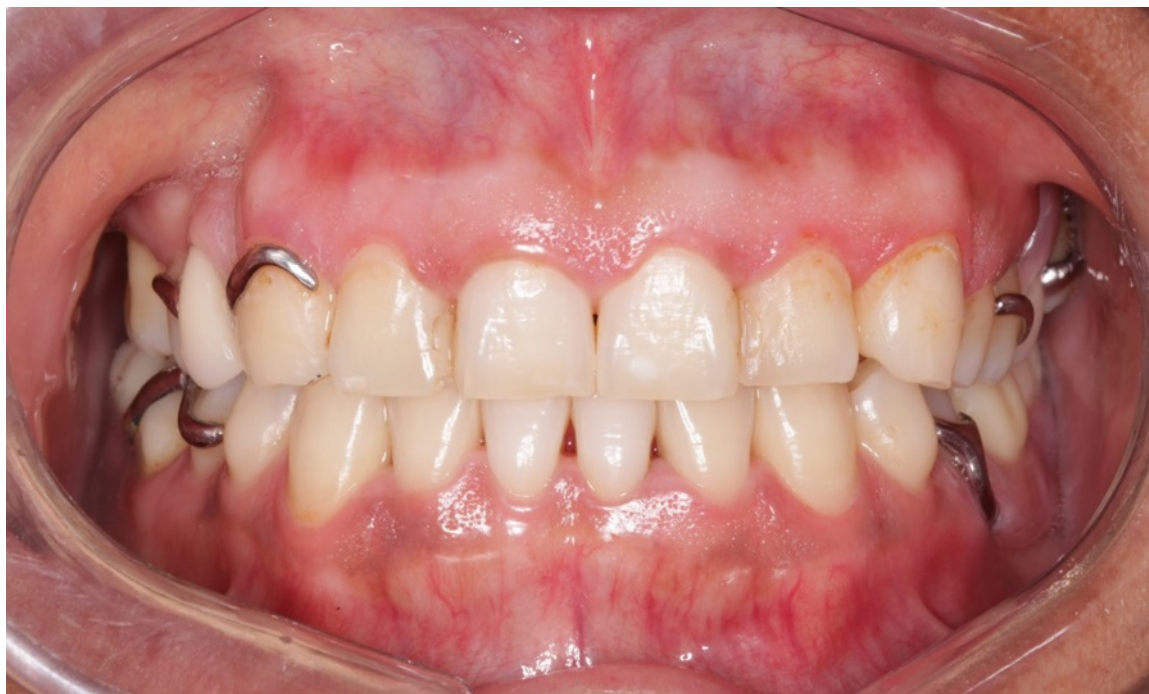➤ INSTALLATION





➤ BEFORE

➤ BEFORE



➤ BEFORE



➤ AFTER





**Secours Dentaire
International**

Dental-Aid International