

CASE 09

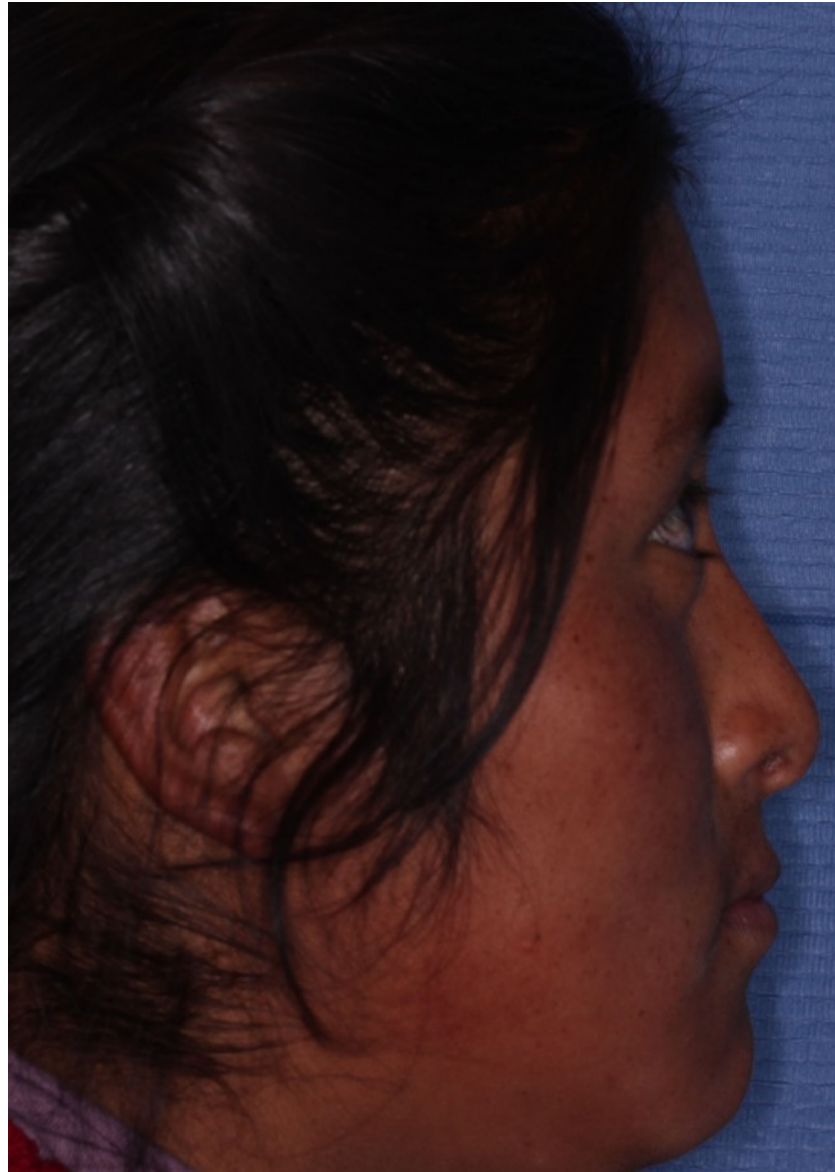
GENERAL INFORMATION:

- **Sex:** Female
- **Age:** 21
- **Address:** Pacchanta - Ocongate
- **Occupation:** Home

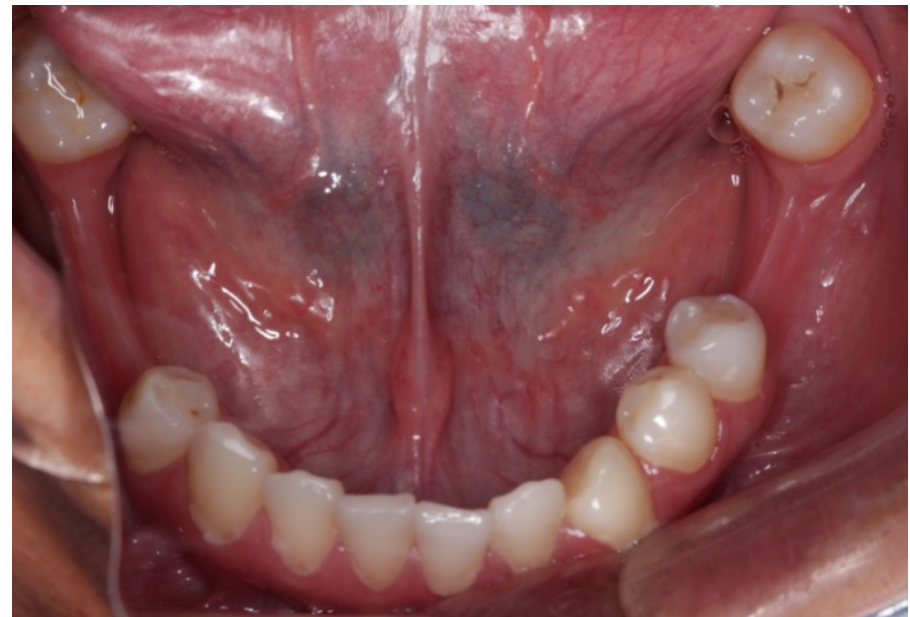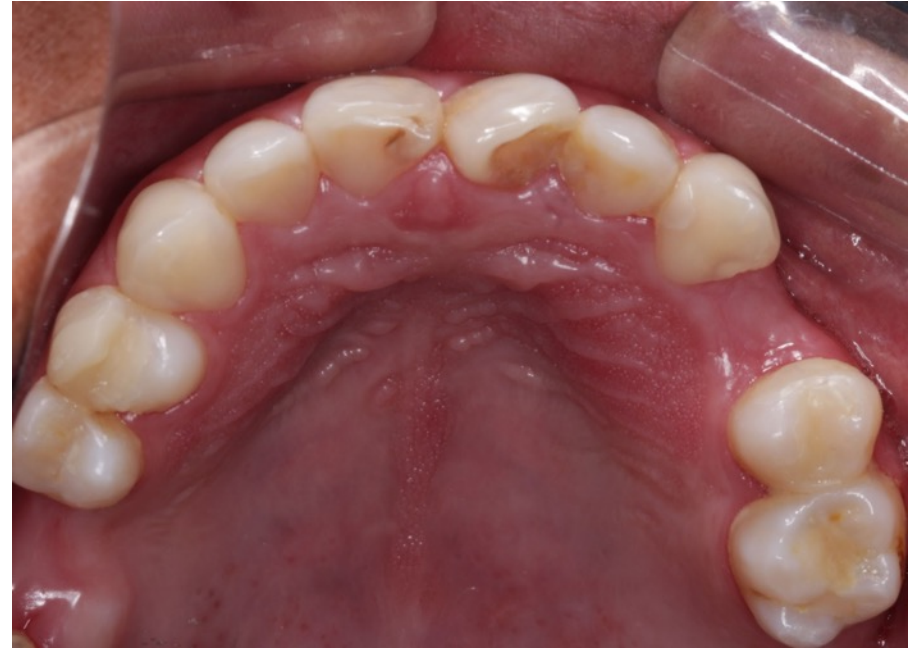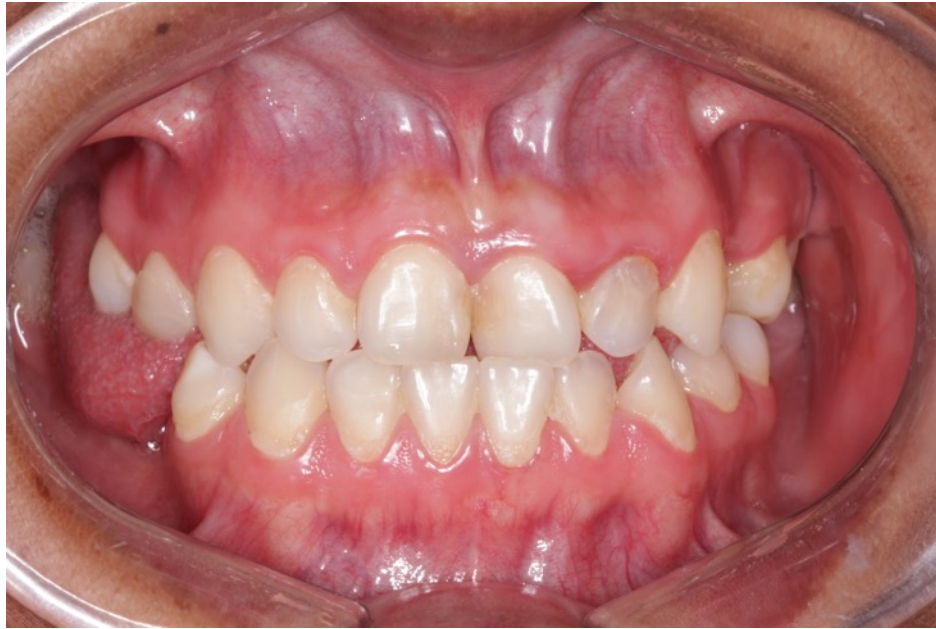EXTRAORAL EXAM - FRONTAL



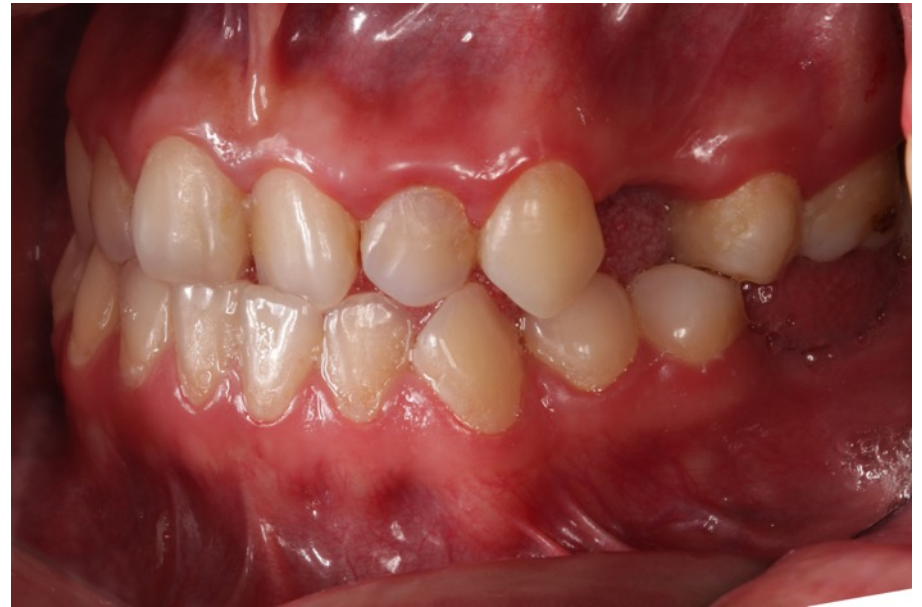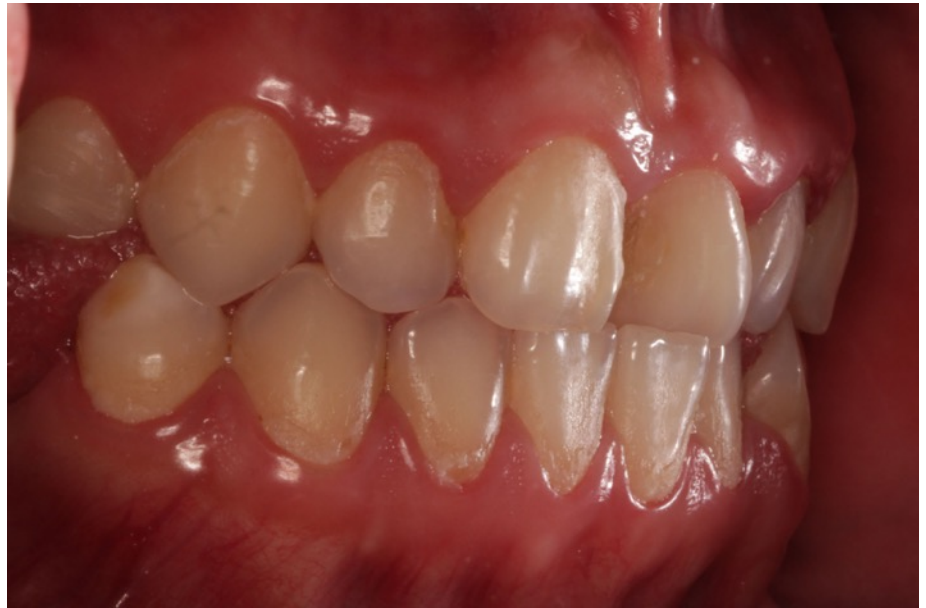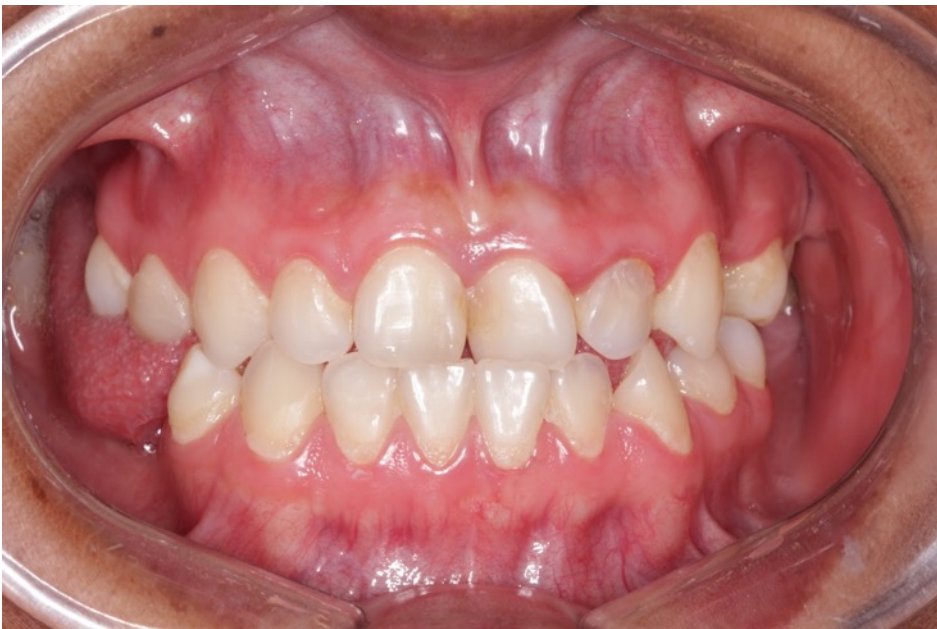EXTRAORAL EXAM - PROFILE



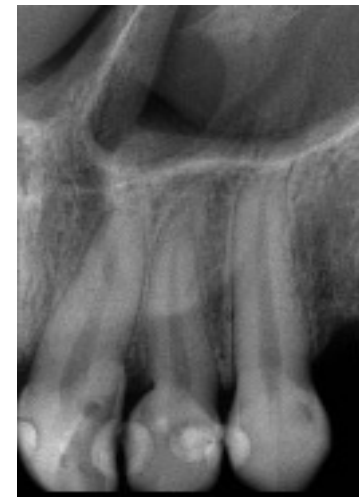INTRAORAL EXAMEN




INTRAORAL EXAMEN



X-RAYS & ODONTOGRAM

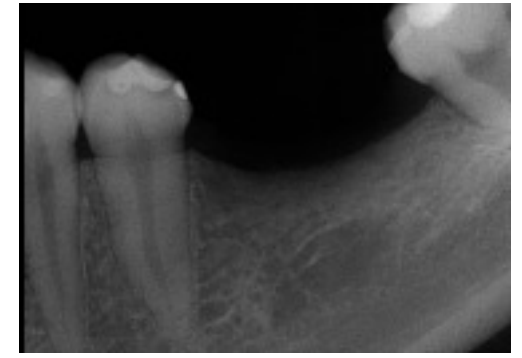
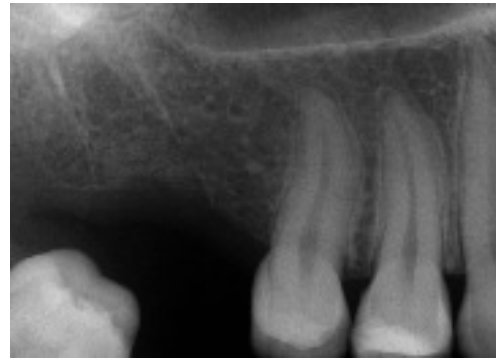

Pieza 2.1 – 2.3



Pieza 1.5 – 1.4

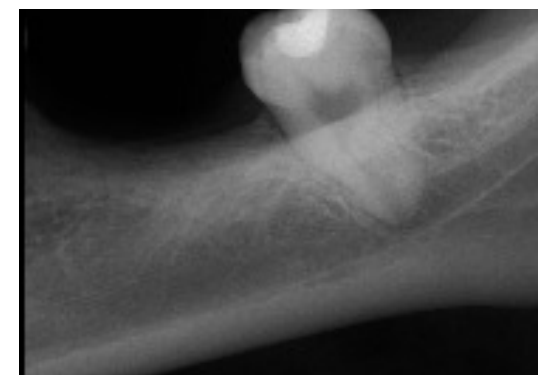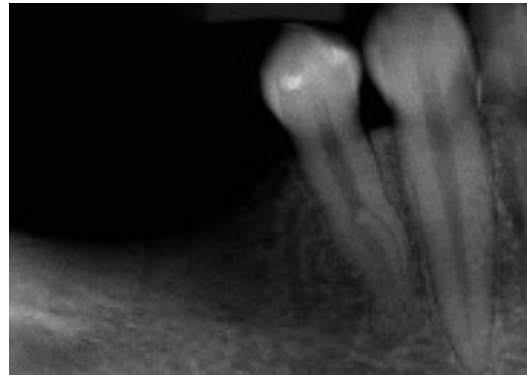
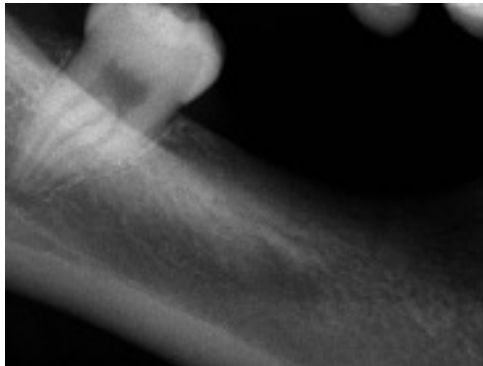
Pieza 3.4



Pieza 4.8

Pieza 4.4

Pieza 3.8



DIAGNOSIS

- Gingivitis associated with plaque
- Dentin caries
- Partial bimaxillary edentulous

TREATMENT

- Dental cleaning
- Fillings
- Bimaxillary dentures

CLINICAL PROTOCOL

CLINICAL PROTOCOL

1st session

- Clinical exam
- Primary impressions
- Cast model parallelization
- Customized trays elaboration

2nd session

- Biostatic preparation
- Definitive impressions

3rd session

- Metal structure try in
- Intermaxillary registration
- Articulation in articulator
- Artificial teeth selection

CLINICAL PROTOCOL

**4th
session**

- Teeth try in

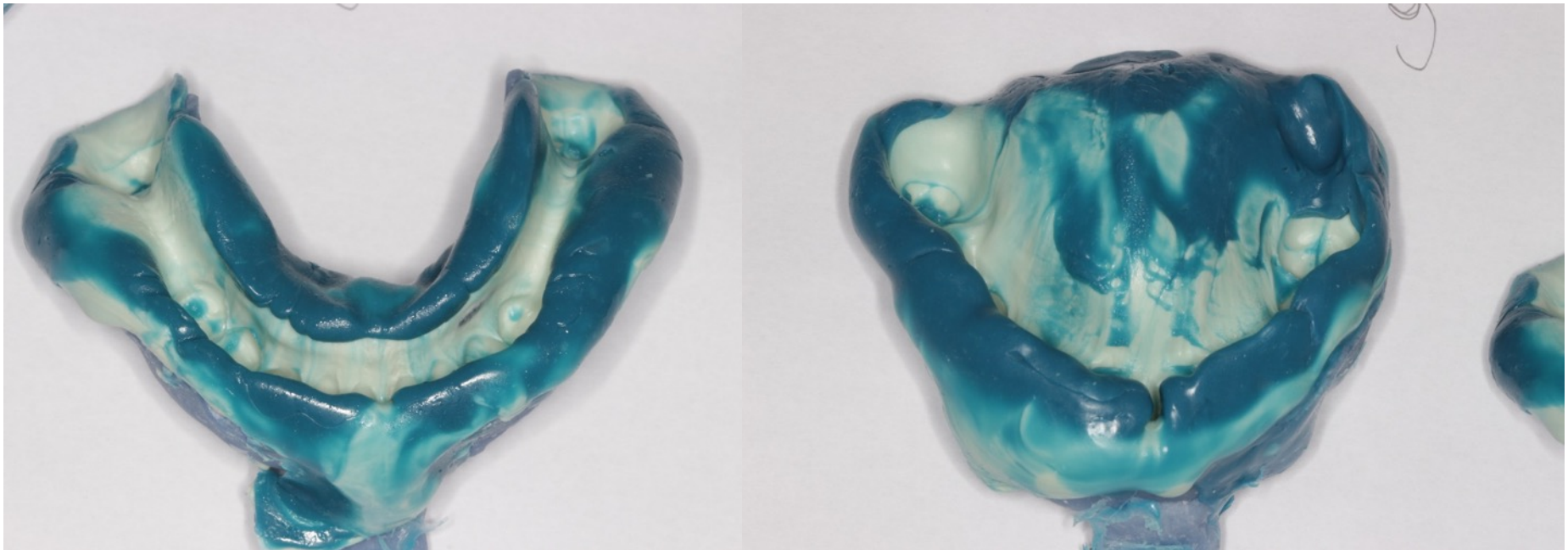
**5th
session**

- Installation

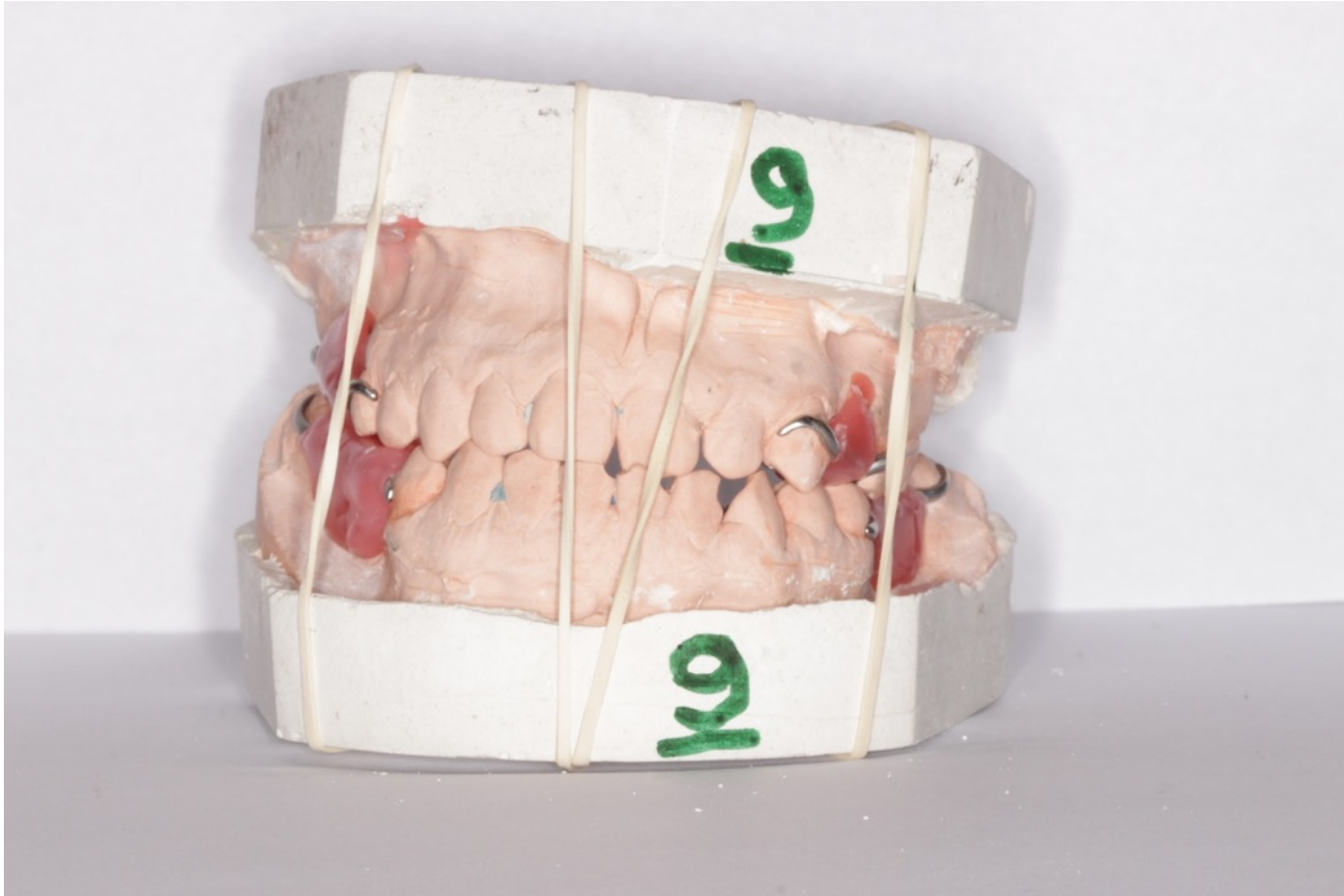**6th
session**

- Follow up

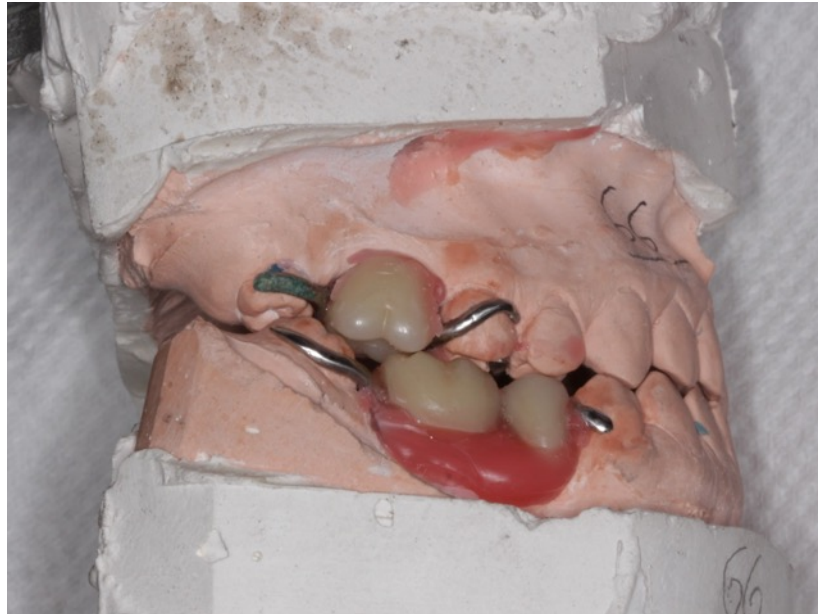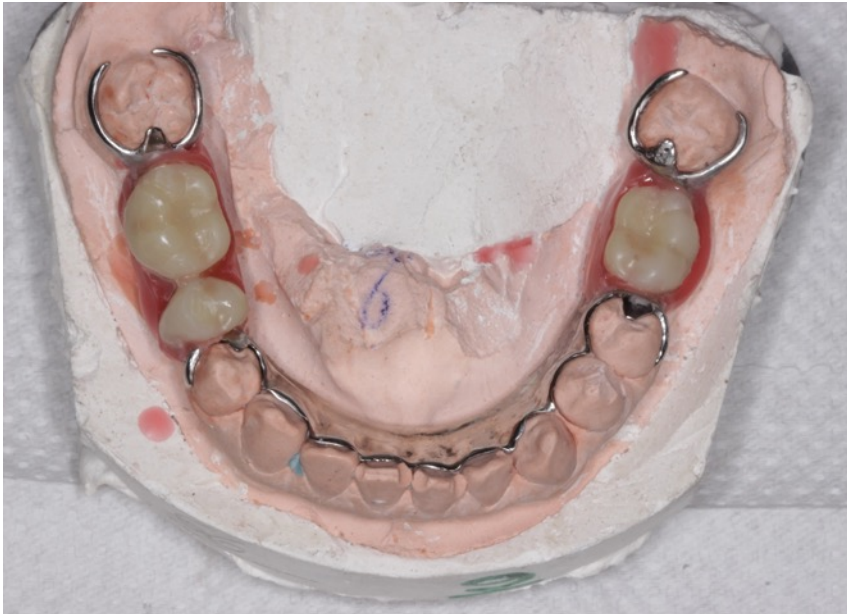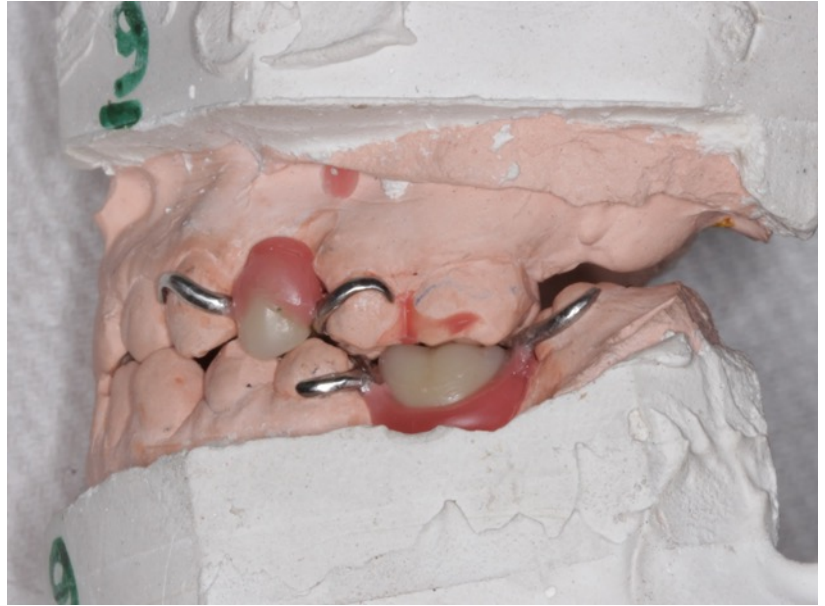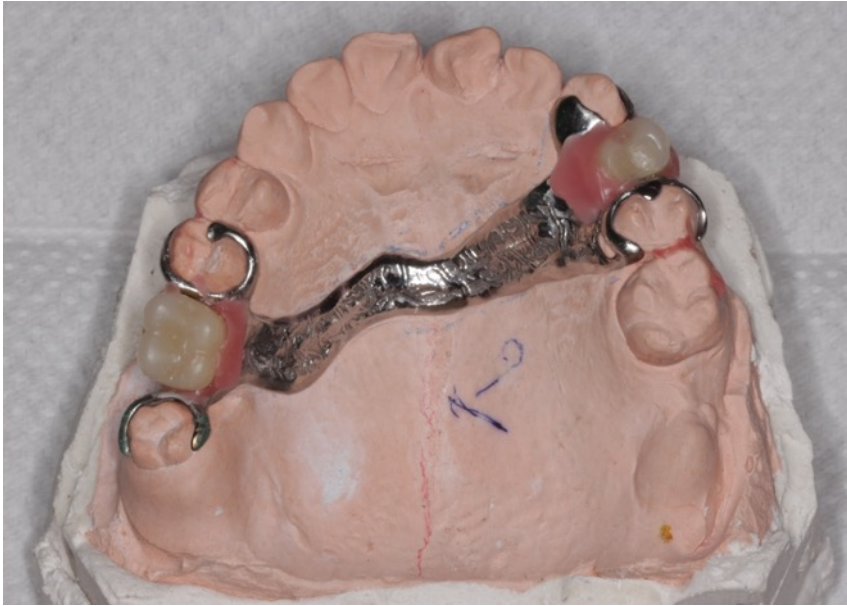
➤ DEFINITIVE IMPRESSIONS



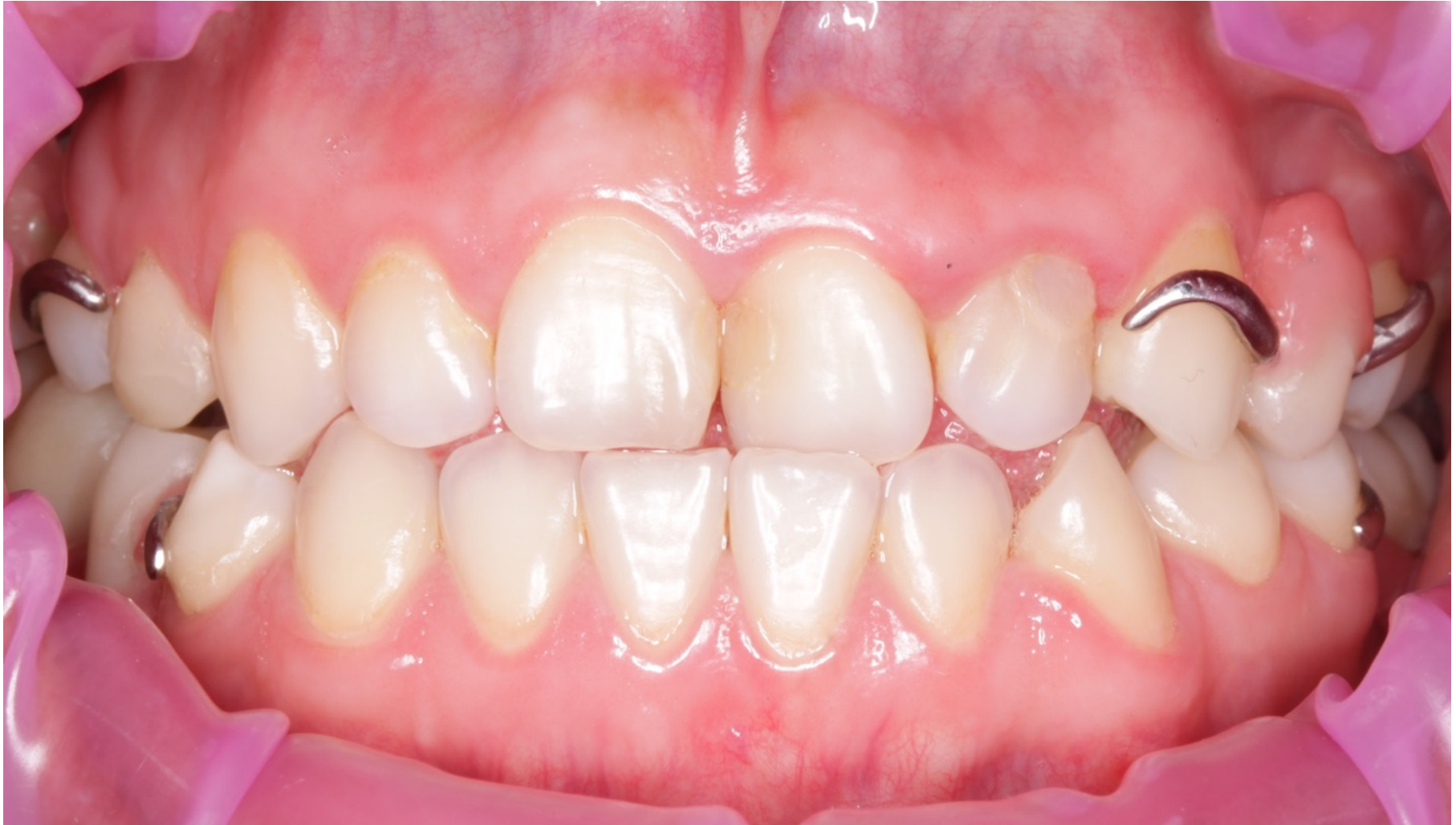➤ INTERMAXILLARY REGISTRATION



➤ WAX UP WITH ACRILIC TEETH



➤ TEETH TRY IN



➤ TEETH TRY IN

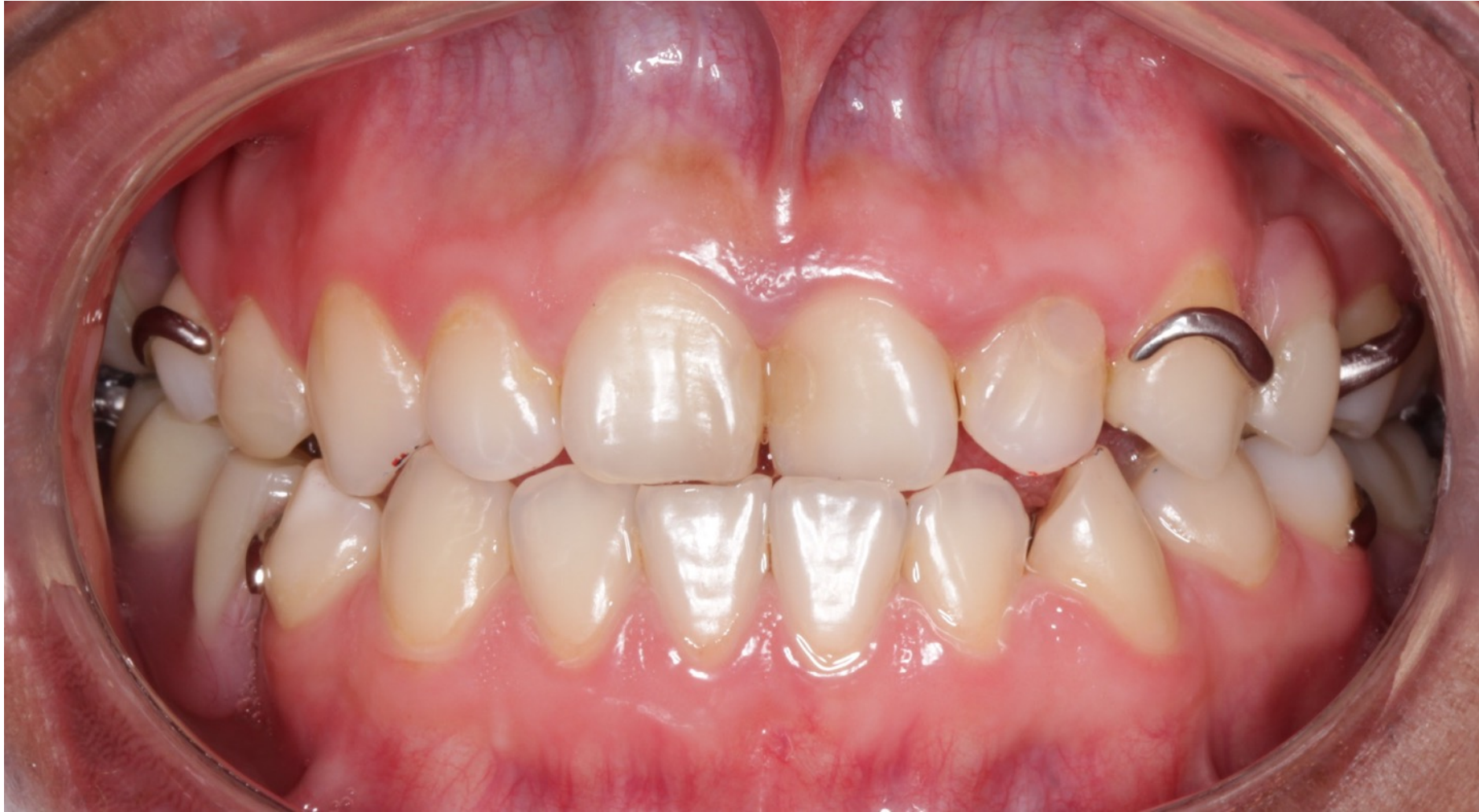

Regular position



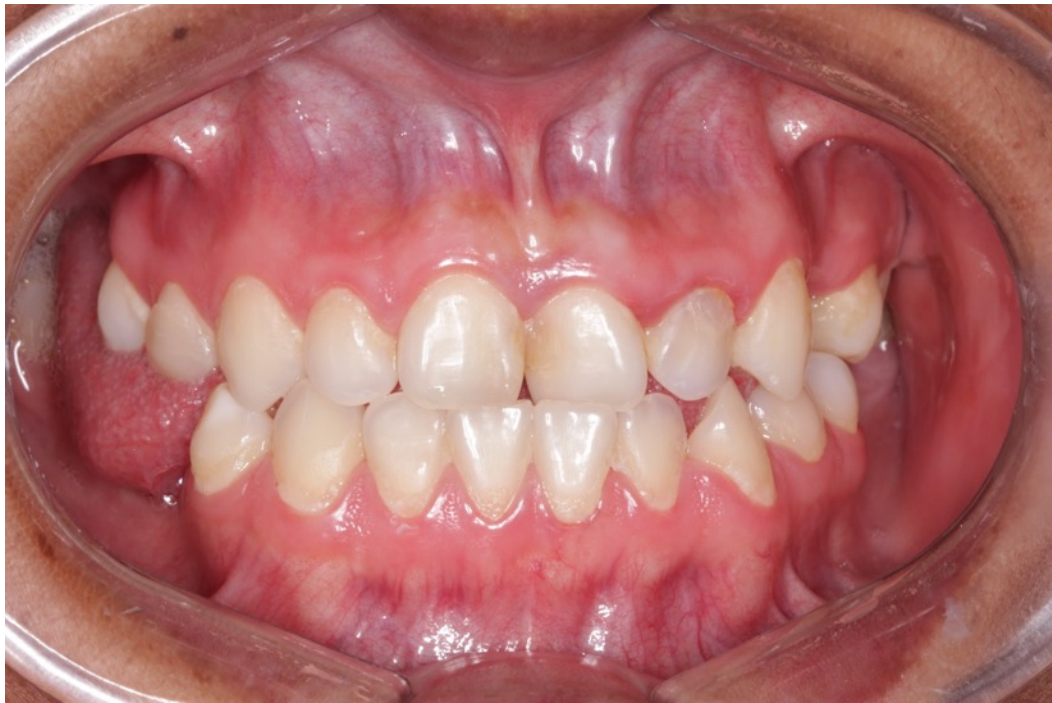Smiling

➤ INSTALLATION



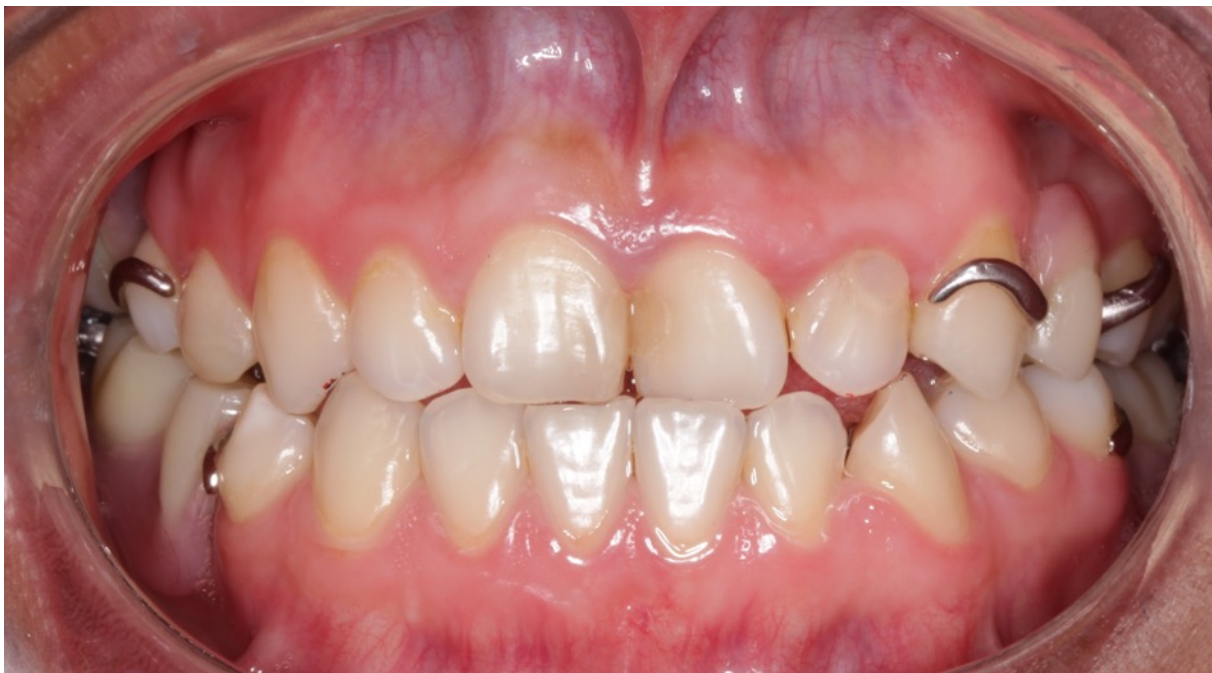➤ INSTALLATION





➤ BEFORE

➤ AFTER



➤ BEFORE

➤ AFTER





**Secours Dentaire
International**

Dental-Aid International