

CASE 10

GENERAL INFORMATION:

- **Sex:** Female
- **Age:** 44
- **Address:** Pacchanta, Ocongate – Cusco
- **Occupation:** Home

EXTRAORAL EXAMEN - FRONTAL

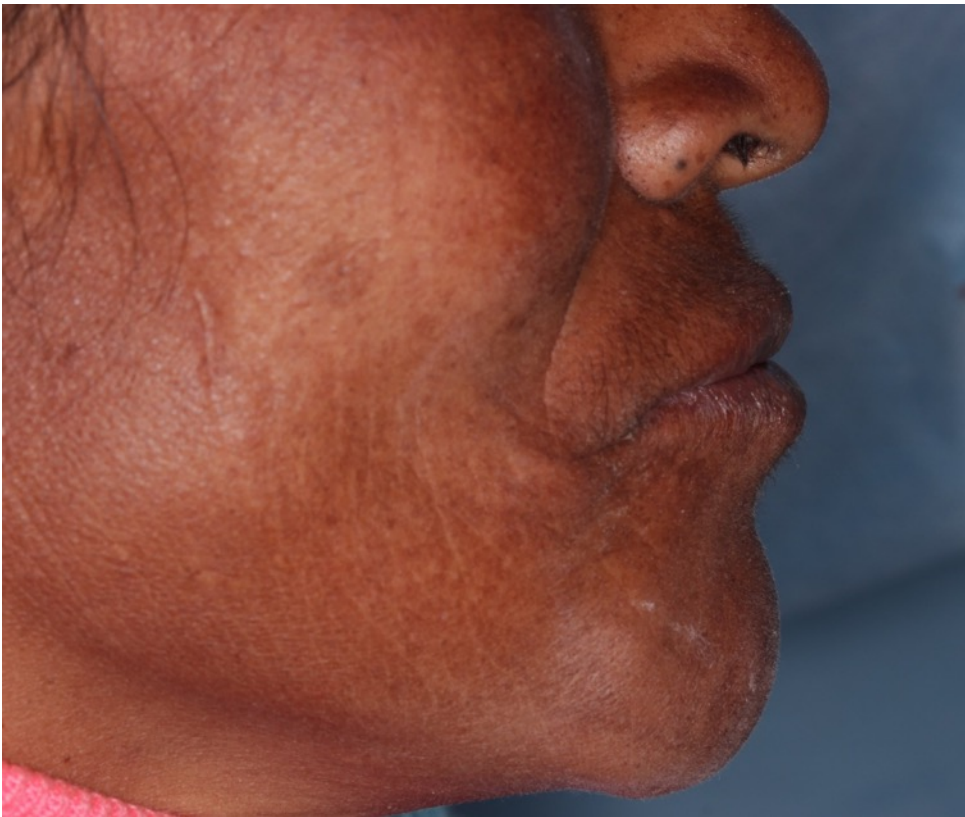

➤ Regular position

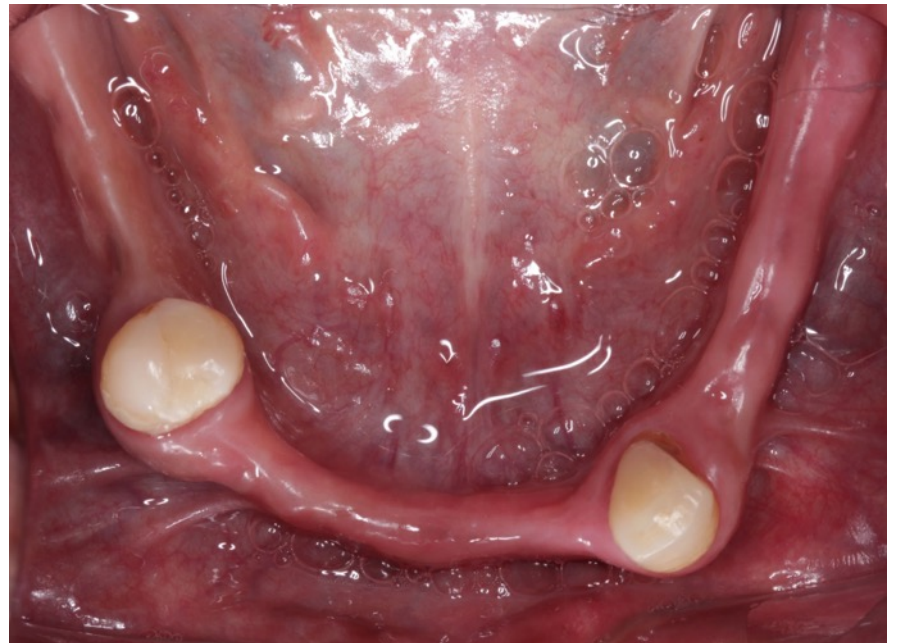
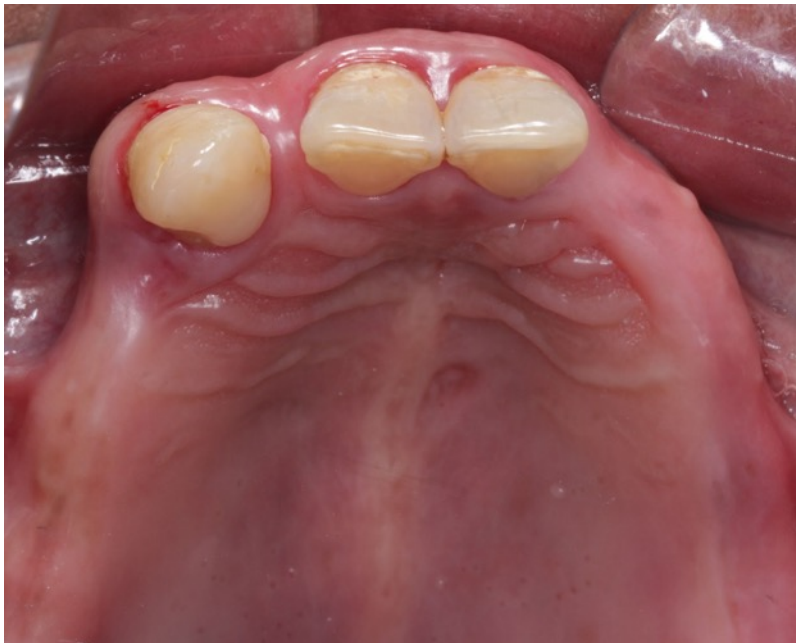
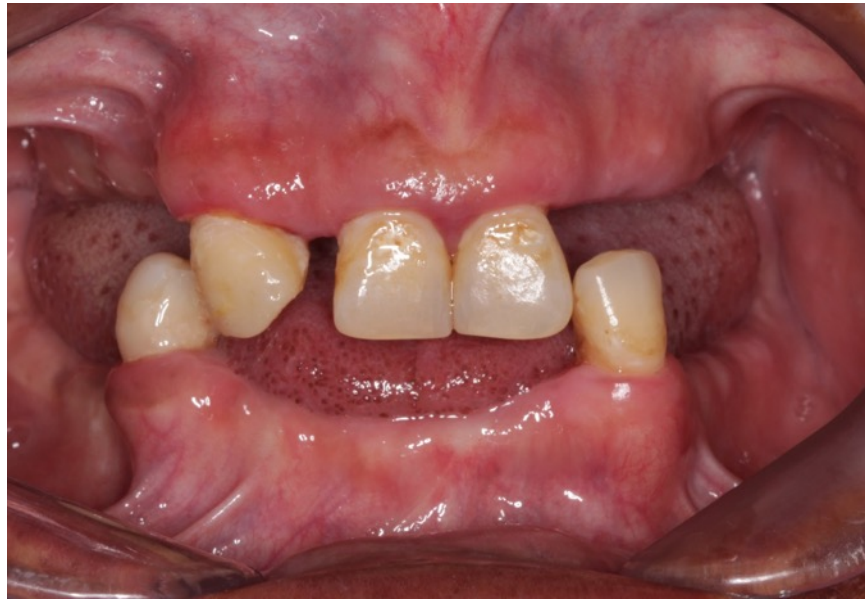
➤ Smiling

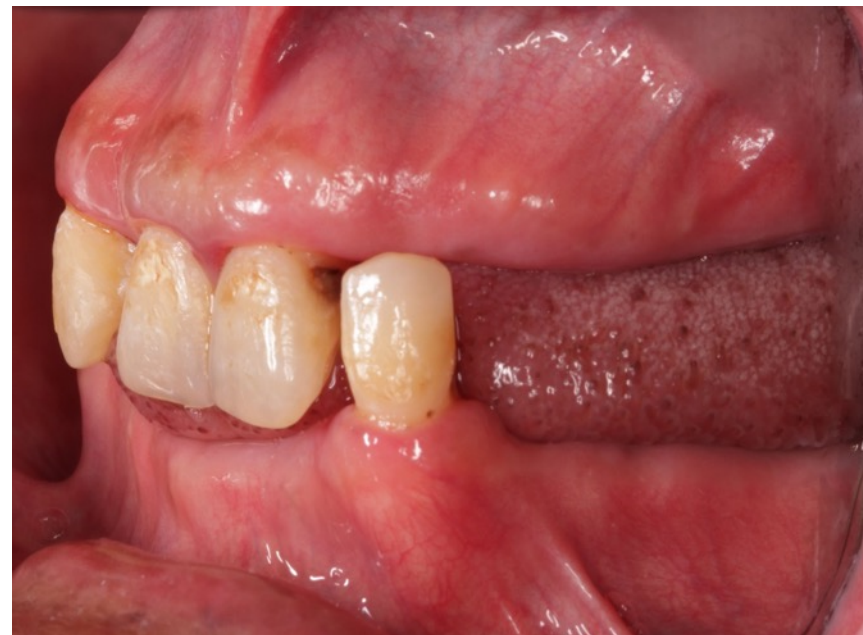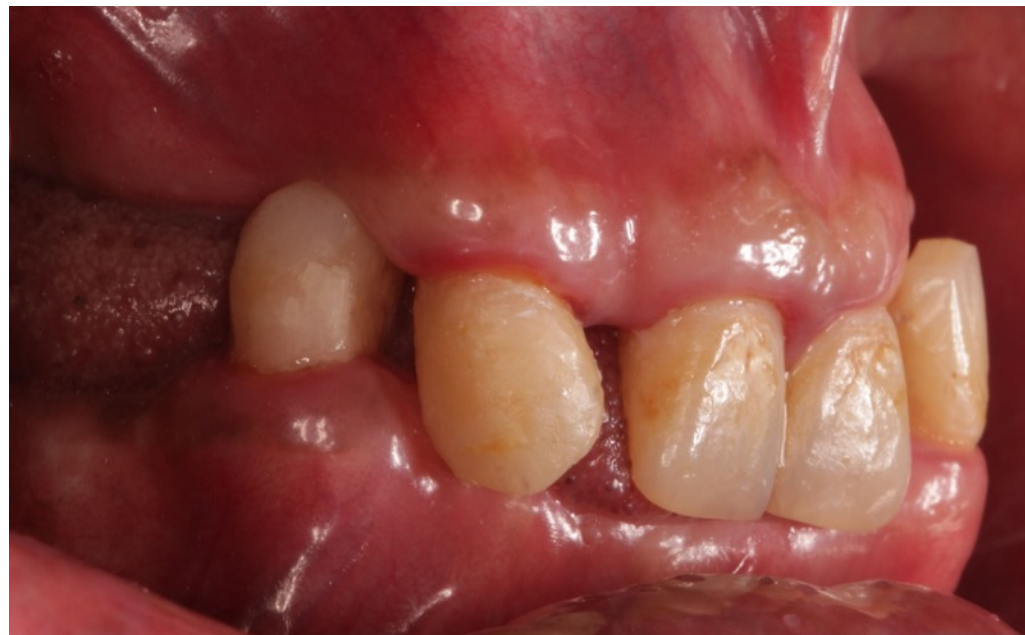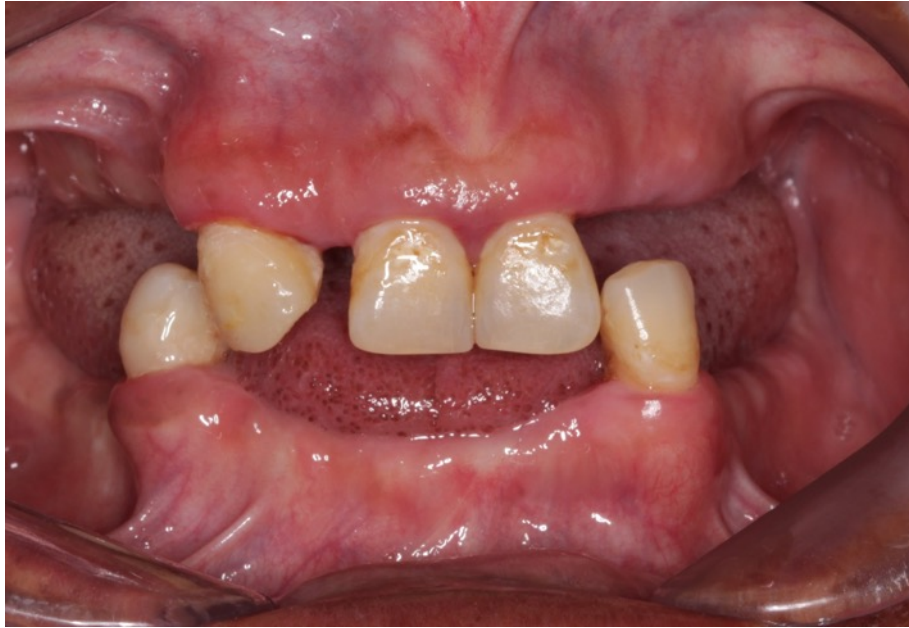EXTRAORAL EXAM – PROFILE



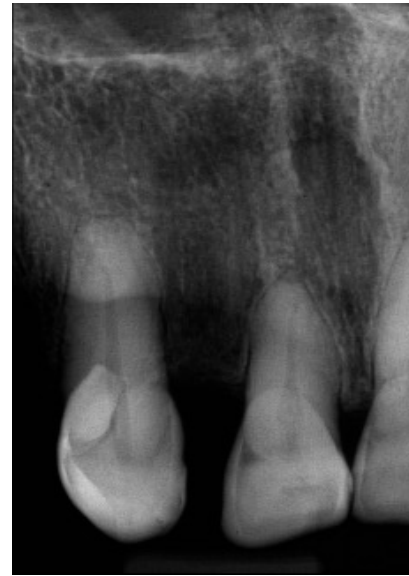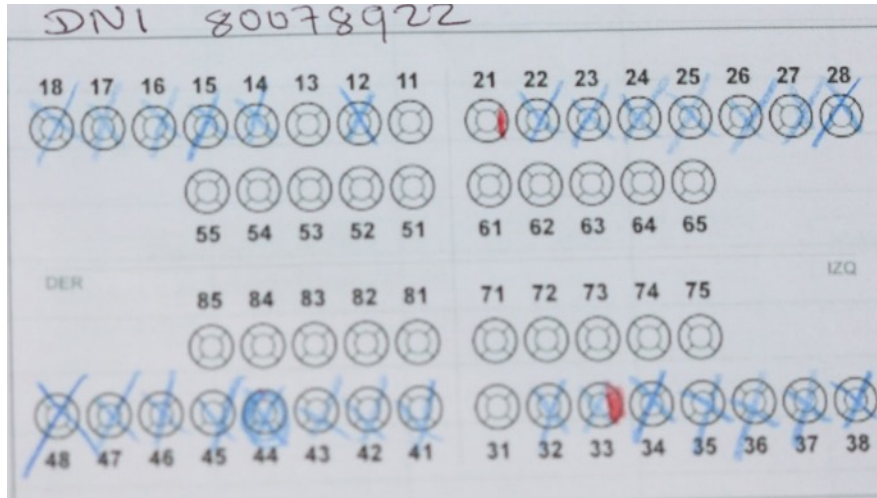
INTRAORAL EXAM



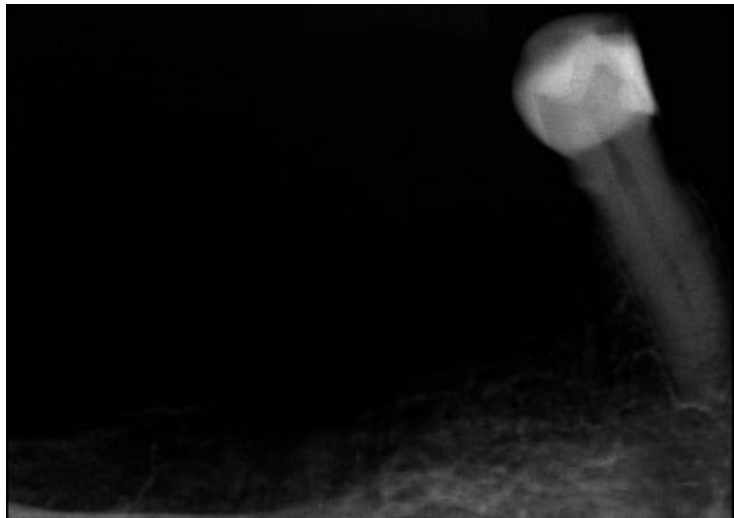INTRAORAL EXAM



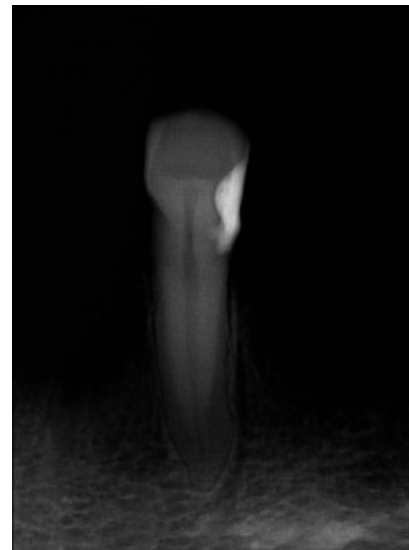X-RAYS & ODONTOGRAM



Tooth 1.3, 1.1, 2.1



Tooth 4.4



Tooth 3.3

DIAGNOSIS

- Gingivitis associated with plaque
- Dentin caries
- Partial bimaxillary edentulous

TREATMENT PLAN

- Dental cleaning
- Fillings
- Bimaxillary dentures

CLINICAL PROTOCOL

CLINICAL PROTOCOL

1st session

- Clinical exam
- Primary impressions
- Cast model parallelization
- Customized trays elaboration

2nd session

- Biostatic preparation
- Definitive impressions

3rd session

- Metal structure try in
- Intermaxillary registration
- Articulation in articulator
- Artificial teeth selection

CLINICAL PROTOCOL

4th
session

- Teeth try in

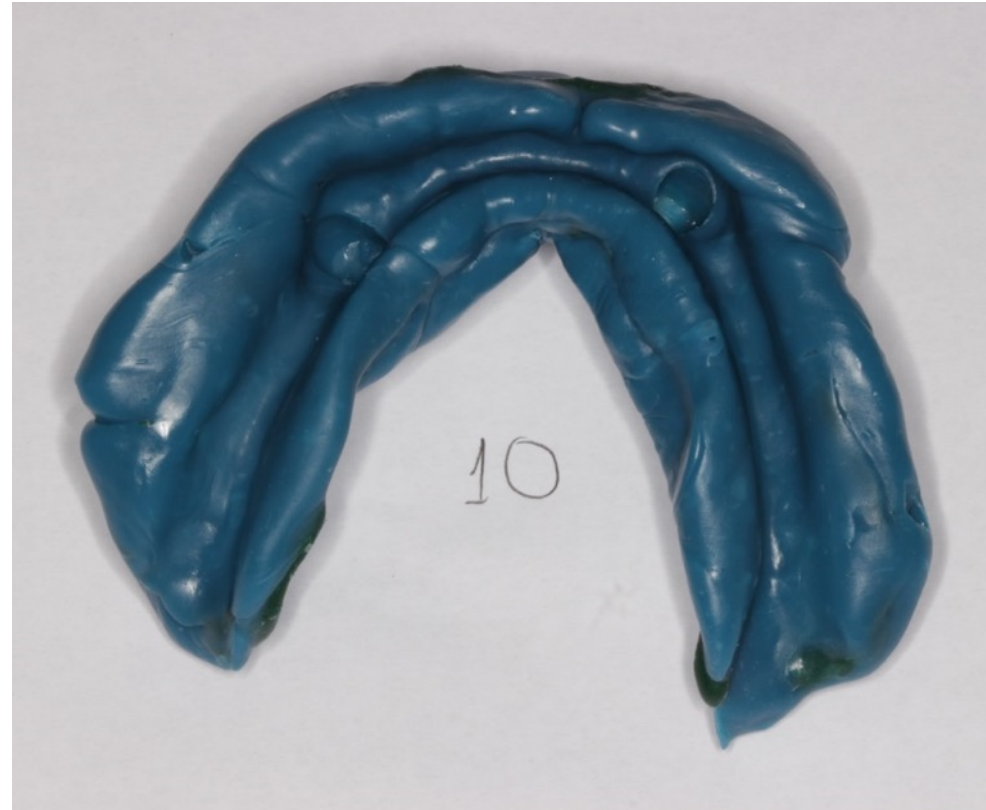
5th
session

- Installation

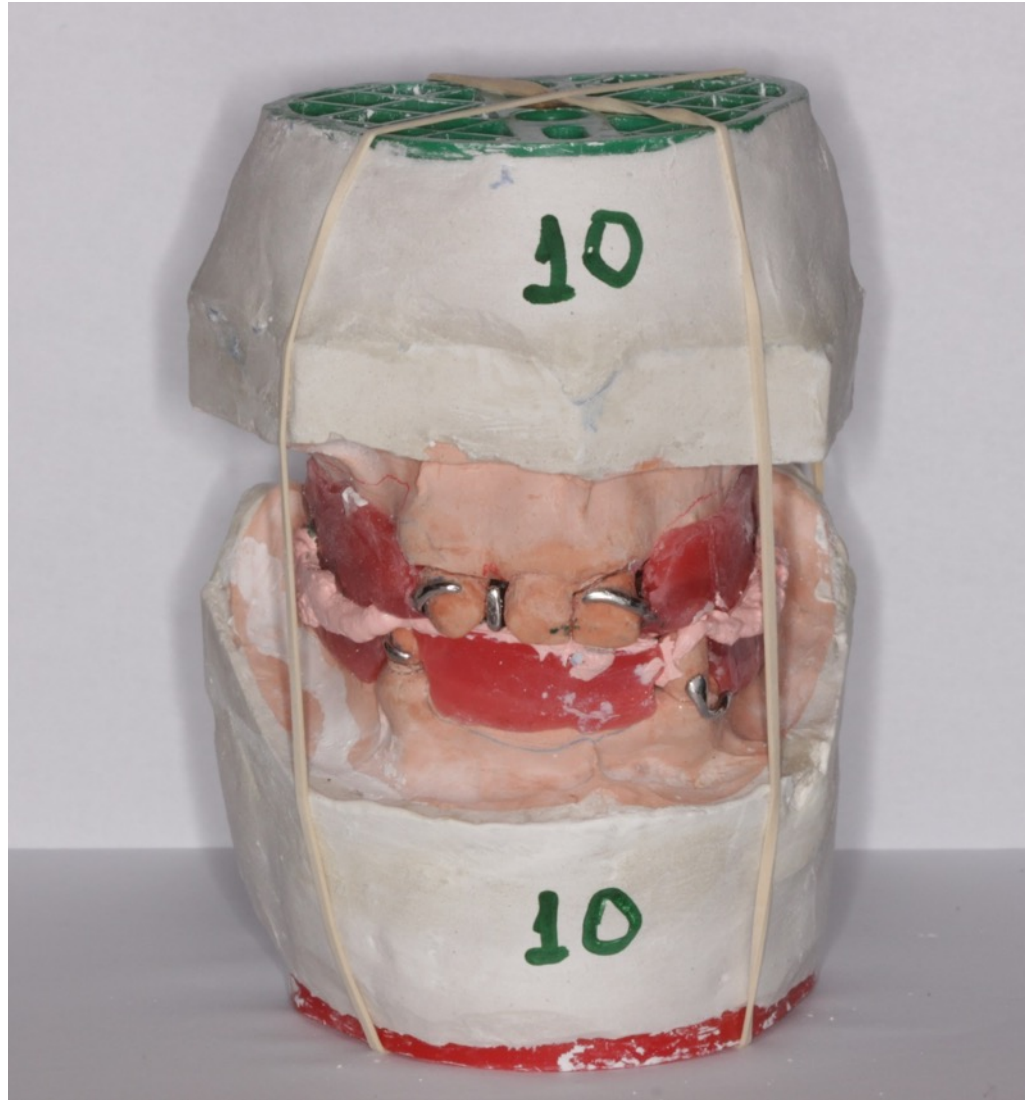6th
session

- Follow up

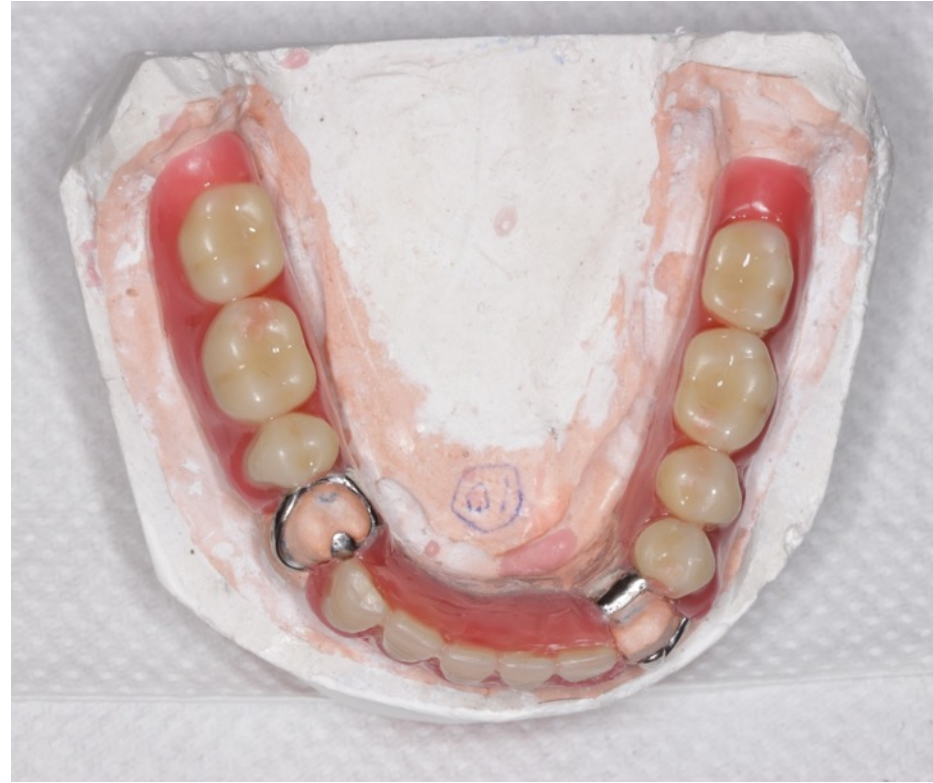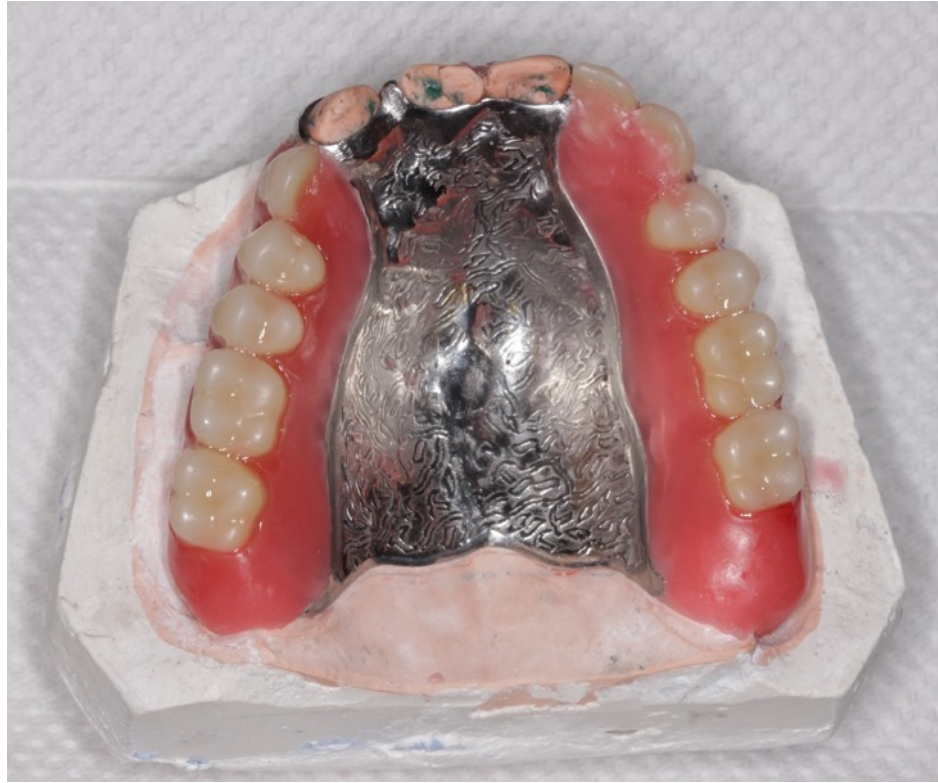➤ DEFINITIVE IMPRESSION



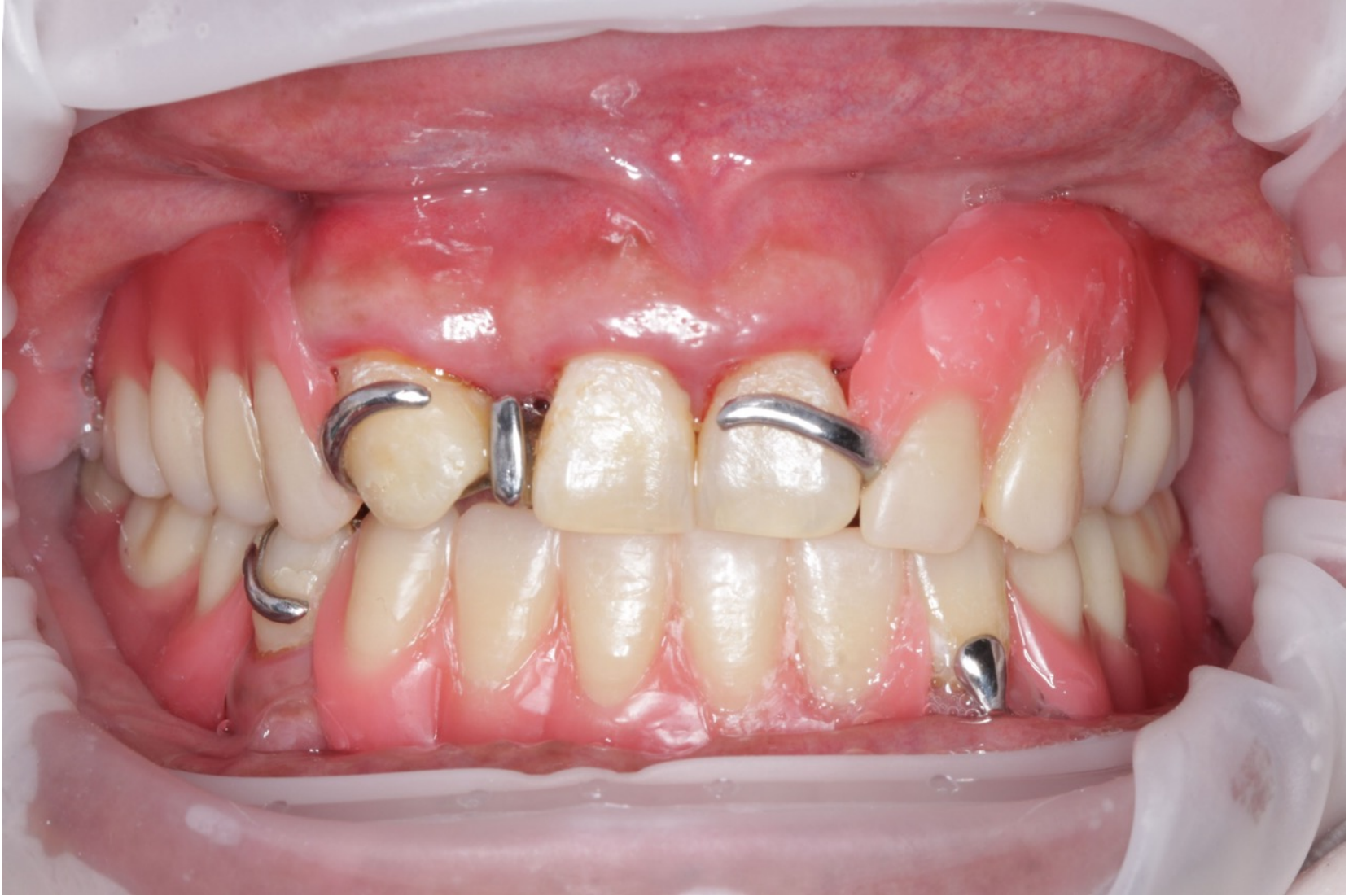➤ INTERMAXILLARY REGISTRATION



➤ TEETH WAX UP



➤ TEETH TRY IN



➤ TEETH TRY IN



➤ En reposo



➤ Sonriendo

➤ TEETH TRY IN

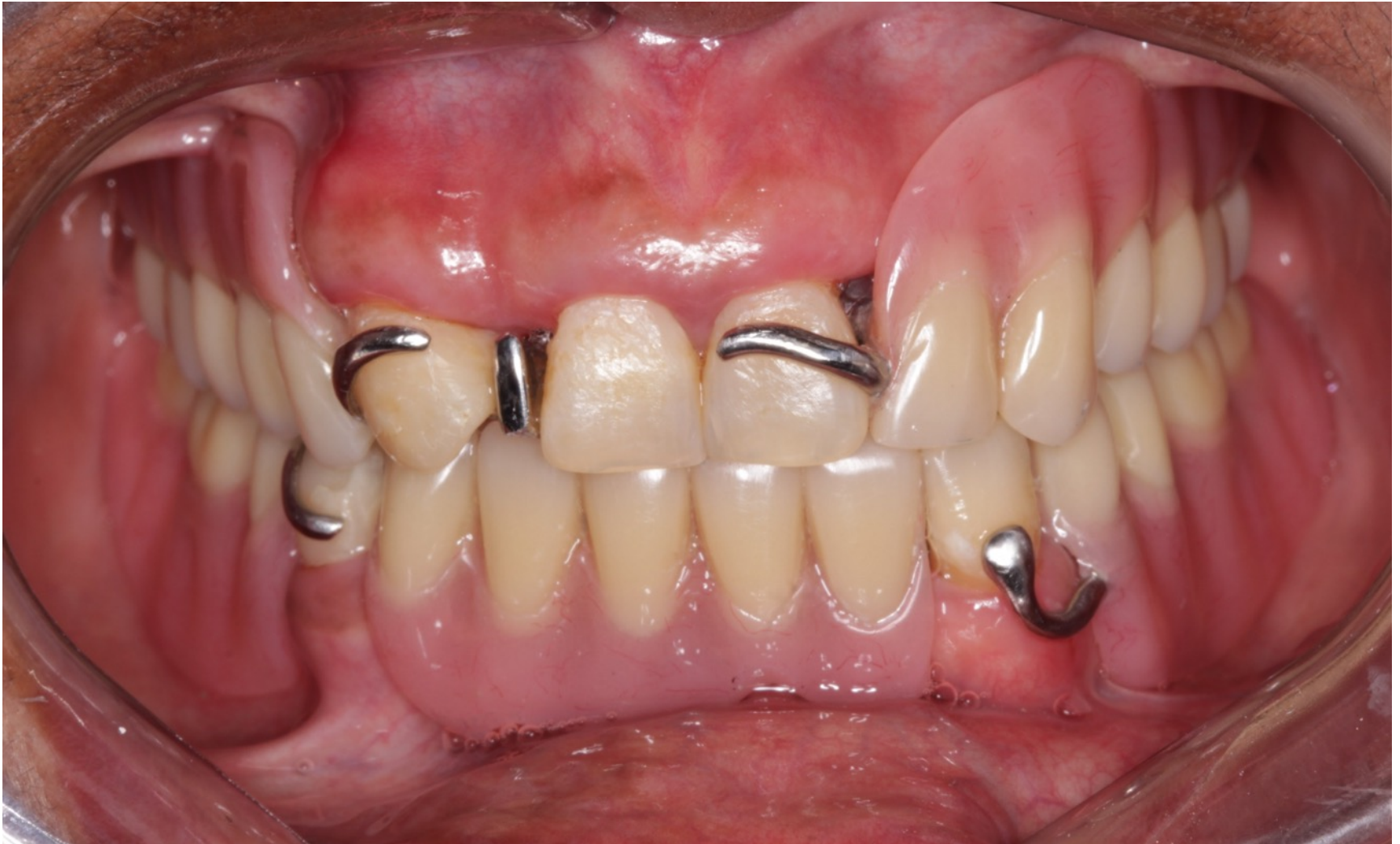

➤ En reposo



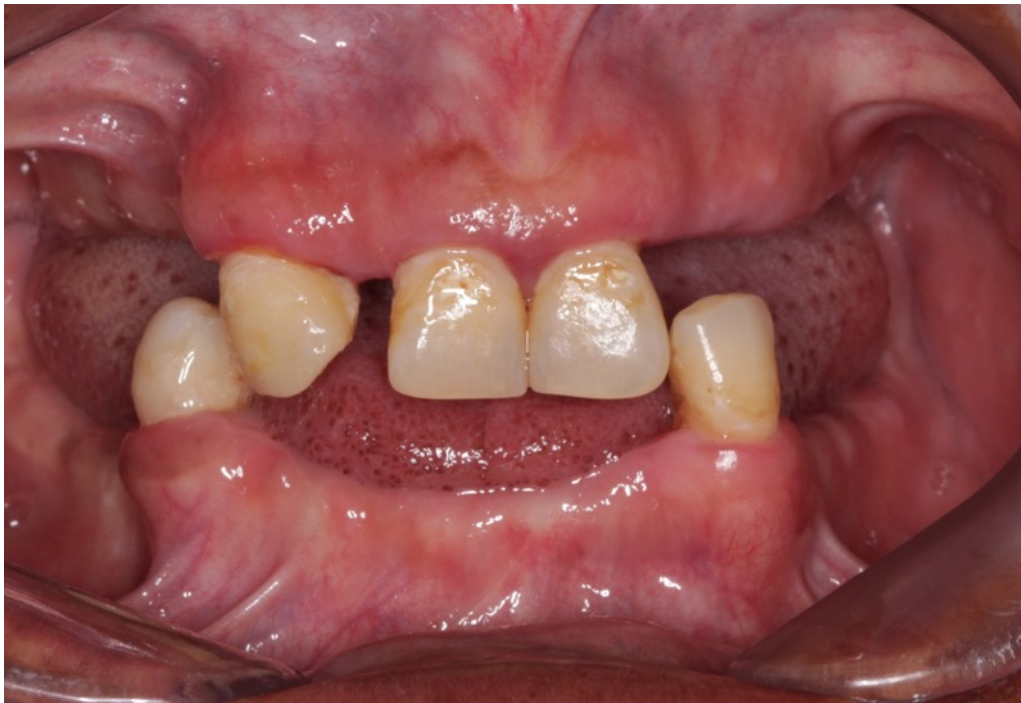➤ Sonriendo

➤ INSTALLATION



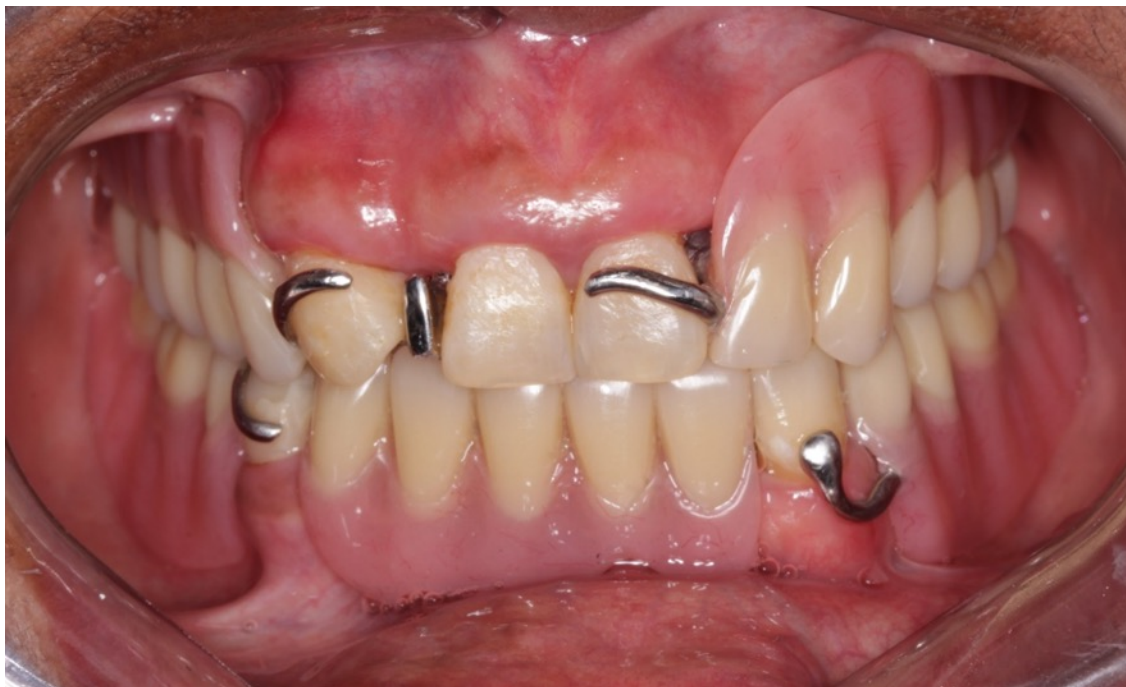➤ INSTALLATION





➤ BEFORE

➤ AFTER



➤ BEFORE

➤ AFTER





con corazón



**Secours Dentaire
International**

Dental-Aid International